Check for updates

Received: 18 March 2022 | Accepted: 18 April 2022

DOI: 10.1002/poh2.6

REVIEW

PH&C PORTAL HYPERTENSION & CIRRHOSIS

MRI in liver cirrhosis

Osama Alzoubi[1] | **Ahmad Arar**[1] | **Viraj Singh**[2] | **Sukru M. Erturk**[3] | **Ferenc Mozes**[4] | **Michael Pavlides**[4,5,6]

[1]School of Medicine, The University of Jordan, Amman, Jordan

[2]School of Public Health, Texas A&M University, College Station, Texas, USA

[3]Department of Radiology, Faculty of Medicine, Istanbul University, Istanbul, Turkey

[4]Radcliffe Department of Medicine, University of Oxford, Oxford, UK

[5]Translational Gastroenterology Unit, University of Oxford, Oxford, UK

[6]Oxford NIHR Biomedical Research Centre, University of Oxford, Oxford, UK

Correspondence

Michael Pavlides, Radcliffe Department of Medicine, University of Oxford, Oxford OX3 9DU, UK.
Email: Michael.pavlides@cardiov.ox.ac.uk

Managing Editor: Ningning Wang

Funding information

None

Abstract

Liver magnetic resonance imaging (MRI) has seen a massive increase in its use over the last decades. Since its first description in the early 1980s, contrast-enhanced MRI is now the gold standard for the diagnosis of hepatocellular cancer in patients with liver cirrhosis. Techniques like magnetic resonance (MR) elastography and combinations of multiple MR parameters in single scanning protocols are now available and these are opening new possibilities for the assessment of multiple aspects of disease in patients with liver cirrhosis. In this narrative review, we provide an overview of the use of MRI in patients with cirrhosis for the diagnosis of and screening for liver cancer, for the diagnosis of cirrhosis and prediction of long-term outcomes, and for the evaluation of portal hypertension. With the multitude of techniques now available and the number of cirrhosis aspects that can be assessed by single scans make the study and application of MRI an attractive target in the search for a technique for use in this group of patients that often have to attend for multiple appointments and multiple tests, including invasive investigations.

KEYWORDS

hepatocellular cancer, imaging biomarker, liver cirrhosis, Liver MultiScan, MR elastography, portal hypertension

Key points

- Contrast-enhanced magnetic resonance imaging is the current gold standard for diagnosis of hepatocellular cancer (HCC) in patients with cirrhosis.
- Magnetic resonance techniques including elastography and Liver MultiScan (Perspectum Ltd.) have recently seen applications in diagnosis and risk stratification of cirrhosis, screening for HCC and ass.

1 | INTRODUCTION

1.1 | Liver disease and cirrhosis

The liver can be affected by a variety of chronic liver diseases (CLDs) like alcohol-related and nonalcoholic fatty liver disease (NAFLD),[1] chronic viral hepatitis B and C, autoimmune conditions like autoimmune hepatitis, and other metabolic disorders like hereditary hemochromatosis, alpha-1-antitrypsin deficiency, and Wilson's disease.[2] All diseases are characterized by a process of repeated liver injury and an aberrant wound healing reaction that leads to the accumulation of liver fibrosis.[3] Accumulation of fibrosis is traditionally described histologically from expansion of fibrosis around the portal tracts to bridging fibrosis and lastly to nodule formation, the latter feature being the defining characteristic of cirrhosis. Patients with cirrhosis are at an increased risk of developing primary liver cancer (hepatocellular cancer; HCC) and portal hypertension, a condition that underlies many liver complications like ascites, hepatic encephalopathy, and variceal bleeding.[2]

In clinical practice, it is therefore important to differentiate patients with cirrhosis from patients with

This is an open access article under the terms of the Creative Commons Attribution-NonCommercial License, which permits use, distribution and reproduction in any medium, provided the original work is properly cited and is not used for commercial purposes.
© 2022 The Authors. *Portal Hypertension & Cirrhosis* published by John Wiley & Sons, Ltd. on behalf of Chinese Medical Association.

noncirrhotic levels or fibrosis. In those with cirrhosis, diagnosis and screening for HCC as well as assessment of portal hypertension are important aspects of care. Imaging with contrast-enhanced CT or MRI is important in the diagnosis of HCC, while ultrasound is recommended as a screening tool for HCC. The diagnosis of cirrhosis and assessment of portal hypertension have traditionally relied on invasive procedures like liver biopsy and measurement of the hepatic vein pressure gradient.

Magnetic resonance (MR) techniques are attractive in the assessment of patients with liver cirrhosis. Unlike ultrasound techniques, MR allows deep penetration into tissues, something that is particularly important in patients with obesity, a condition that has reached epidemic levels in many populations. Furthermore, MRI does not use ionizing radiation and therefore repeated scans can be performed without safety concerns from repeated radiation exposure. Therefore, MR technologies have seen applications for the assessment of many aspects of liver cirrhosis, and the aim of this article is to provide a narrative review of the literature that examined MR for the diagnosis and screening of HCC in patients with cirrhosis, for the diagnosis of cirrhosis and the prediction of complications in these patients, and for the evaluation of portal hypertension.

1.2 | MR techniques

The concept of nuclear MR which forms the basis of MR imaging was initially described by Bloch et al.[4] and Purcell et al.[5] in the mid-1940s, and this technique was used to acquire images in the 1970s.[6] The first body and head scans were published by 1980,[7] and MR liver application was examined soon after in studies published in 1981–1982.[8,9] Even in these early studies,[8,9] it was noticed that patients with liver cirrhosis, CLDs, and hepatoma had different MR characteristics compared to healthy controls. Since those initial studies, a variety of MR techniques have been developed. Techniques currently established in clinical practice are mainly qualitative techniques that produced anatomical images that require interpretation by a radiologist. Emerging techniques, on the other hand, are quantitative and can provide a wealth of information beyond anatomical detail. Such quantitative techniques include proton density fat fraction (PDFF) estimations as surrogates of liver fat,[10] T1 mapping[11] techniques as estimates of fibrosis and inflammation, and magnetic resonance elastography (MRE)[12] techniques as estimates of fibrosis.

2 | MRI FOR DIAGNOSIS OF HCC

Diagnosis of HCC is the main current indication for contrast-enhanced MRI in patients with cirrhosis. Vascular derangements that develop during the development of HCC[13] lead to the specific imaging characteristics of dynamic contrast-enhanced (DCE) imaging (arterial phase hyperenhancement and washout on portal venous phase or delayed phase). This observation, combined with the high pre-test probability of HCC in patients with cirrhosis[14,15] means that in these patients, HCC can be diagnosed based on imaging features alone without the need for histological evaluation. The radiological diagnosis of HCC in patients with cirrhosis has been standardized in the Liver Imaging Reporting and Data System (LI-RADS),[16] a comprehensive quality assurance tool for all aspects of radiological diagnosis of HCC including interpretation and reporting of imaging studies in patients with cirrhosis.

Both contrast-enhanced CT and MRI can be used for the diagnosis of HCC in patients with liver cirrhosis and several studies[17–19] have compared the diagnostic accuracy of the two modalities. In general, MRI has higher sensitivity, particularly for smaller lesions.

For the characterization of HCC, extracellular contrast agents or liver-specific contrast agents (gadoxetate) can be used. The extracellular agents can be used to characterize the classical HCC features of arterial hyper-enhancement and late phase washout. Liver-specific MRI contrast agents like gadoxetate, are taken up by hepatocytes and excreted in bile and can provide further information on focal liver lesions. There is still debate on whether liver-specific agents offer an advantage over extracellular agents for the diagnosis of HCC with LI-RADS[16] still listing the features from liver-specific agents as ancillary features and not part of the diagnostic classification, but other guidelines accept features from liver-specific contrast-enhanced scans as alternatives to portal phase washout.[20] One study, in particular, showed that adding a hepatobiliary phase to the dynamic MRI protocol led to improved sensitivity and negative predictive value.[18] Furthermore, a recent meta-analysis has provided further support for the use of liver-specific gadolinium contrast showing that the inclusion of transition phase or hepatobiliary phase hypointensity in the definition of washout improved the sensitivity for HCC in LI-RADS.[21]

3 | MRI TO SCREEN FOR HCC

HCC in patients with compensated liver cirrhosis can be cured with surgical resection or liver transplantation if detected early. However, ultrasound, the currently recommended modality to screen for HCC in these patients has a low sensitivity for early HCC (28%–47%).[22,23] Therefore, despite surveillance with ultrasound scans (USS), many cancers are detected at an advanced stage something that limits curative treatment options. Many investigators have therefore examined MRI as a screening tool for HCC in these patients. While literature in this field is accumulating and has now been subject to systematic reviews,[24,25] the majority of the data to support the use of MRI come from retrospective case-control studies that cannot be compared with the data supporting the use of USS that on the whole come from prospective cohort studies.[23] There are only two prospective studies that have undertaken a head-to-head comparison between MRI and USS.

27705846, 2022, 1, Downloaded from https://onlinelibrary.wiley.com/doi/10.1002/poh2.6 by Cochrane Canada Provision, Wiley Online Library on [12/12/2023]. See the Terms and Conditions (https://onlinelibrary.wiley.com/terms-and-conditions) on Wiley Online Library for rules of use; OA articles are governed by the applicable Creative Commons License

The first study was an 18-month prospective study of 407 patients with cirrhosis and an estimated annual risk of HCC > 5% in a tertiary center.[26] The study was designed to examine the diagnostic performance of MRI with liver-specific contrast as compared to USS. However, after the study was completed, the European Medicines Agency restricted the use of liver-specific gadolinium agents over concerns of gadolinium accumulation in the brain.[27] Therefore, contrast-enhanced MRI scans cannot be justified as screening tests. The investigators conducted a post hoc analysis of the noncontrast-enhanced MR images in their data set. This showed that noncontrast-enhanced MRI had superior sensitivity (79% vs. 28%) and comparable specificity (98% vs. 95%) to the standard of care USS.[22] Based on these results, the investigators are now planning a single-center randomized study of 416 patients to evaluate whether noncontrast-enhanced MRI leads to improved survival compared to USS.[28]

A study from Australia examined the use of MRI diffusion-weighted imaging (DWI) to screen for HCC in patients with liver cirrhosis.[29] The sensitivity of USS was higher in this study, detecting all six cancers that developed in the duration of follow-up, while MRI DWI missed one HCC. Furthermore, this study suffered from the attrition of approximately 50% after each round of screening with 192 patients included at the start of the study but only six (3%) patients returning for the fifth round of screening, something that raises concern about the applicability of MRI in this context.

While the accumulating data provide some encouragement for the use of MRI as a screening tool for HCC in patients with liver cirrhosis, significant data gaps remain to be addressed before a firm conclusion can be made and these have been pointed out in recent correspondence.[30,31] In particular, the literature evaluating MRI in prospective head-to-head studies with USS is limited and with conflicting data as discussed above. Furthermore, studies have so far focused on whether MRI can improve the diagnosis of HCC, but there are no data exploring whether the application of MRI to screen for HCC leads to improved survival of patients. While it may be expected that improved cancer diagnosis would lead to improved survival this is not always the case as shown by a recent study evaluating screening strategies for ovarian cancer.[32]

4 | MRI FOR THE DIAGNOSIS OF LIVER CIRRHOSIS

Accurate staging of liver fibrosis is considered crucial and fundamental for disease prognosis and management decisions,[33] especially in these days where NAFLD is now considered a worldwide epidemic, with its known association with steatohepatitis and sometimes asymptomatic fibrosis.[34] The importance of accurate liver fibrosis staging originates from the fact that early fibrosis can be reversible, and thus silent disease progression can be halted by certain interventions (like antiviral medication in viral hepatitis),[35,36] highlighting major benefits to the patients.

Although the gold standard for evaluating and staging liver fibrosis up to this moment remains the histopathological examination of core needle liver biopsies, this is far from being perfect and has major drawbacks. First of all, liver biopsy is an invasive procedure, and it can be complicated by pain, bleeding, pneumothorax, biliary tree puncture, and death (approximately 1 in 10,000–12,000).[37,38] Furthermore, liver biopsy has a significant sampling error of up to 14.5%–25%, poor reproducibility as well as difficult repeatability for follow-up purposes.[39,40] Cost and interobserver variability can also be problematic in certain situations.[37,41]

Moreover, since liver fibrosis is far from being a homogenous process, questions were raised not only about the invasiveness and impracticality of the liver biopsy but also about its accuracy. Specimens obtained by core needle liver biopsy represent approximately 1/50,000 of the total liver volume, and this could be inaccurate for precise liver evaluation, as the accuracy of liver fibrosis staging with biopsy depends on specimen size.[40,42,43] This does not count for postsurgical liver specimens, which provide a much larger specimen size compared to core needle biopsies.

These drawbacks motivated researchers to head toward noninvasive alternatives to liver biopsy. Multiple methods were described in the literature to evaluate liver fibrosis and cirrhosis, and in this review, more focus will be given to the MRI-based methods for this purpose. It is worth mentioning currently, noninvasive markers such as NAFLD fibrosis score,[44] and Enhanced Liver Fibrosis (ELF™) Test[45] are not considered to be sufficiently accurate for routine clinical use as diagnostic tests. Like serum-based biomarkers and ultrasound-based elastography biomarkers, a number of studies have examined MR techniques for the assessment of liver fibrosis and diagnosis of cirrhosis.

5 | MRE

Fibrosis progression and cirrhosis change the liver from being one of the softest tissues in human beings,[46] to a stiffer and harder tissue that can be appreciated upon palpation.[47] This concept forms the background of using MRE to evaluate liver fibrosis, which is a quantitative technique to measure the mechanical properties of the liver depending on the concept that propagating mechanical waves move more rapidly in a stiff liver than a soft liver.[48,49] It works by generating mechanical waves and tracking the waves as they pass through the liver and accordingly measures the frequency of the and finally forming an elastogram that reflects liver stiffness[48,49] (Figure 1). Actually, MRE is not the only available elastography technique, and others include ultrasound transient elastography (TE) and point shear wave elastography (pSWE).[50–52]

Several studies have now examined MRE for the diagnosis of cirrhosis. The study by Morisaka et al.[53] carried out a comparison between liver histology from core needle biopsy and MRE using postsurgical pathology results as their reference standard. The study

27705846, 2022, 1, Downloaded from https://onlinelibrary.wiley.com/doi/10.1002/poh2.6 by Cochrane Canada Provision, Wiley Online Library on [12/12/2023]. See the Terms and Conditions (https://onlinelibrary.wiley.com/terms-and-conditions) on Wiley Online Library for rules of use; OA articles are governed by the applicable Creative Commons License

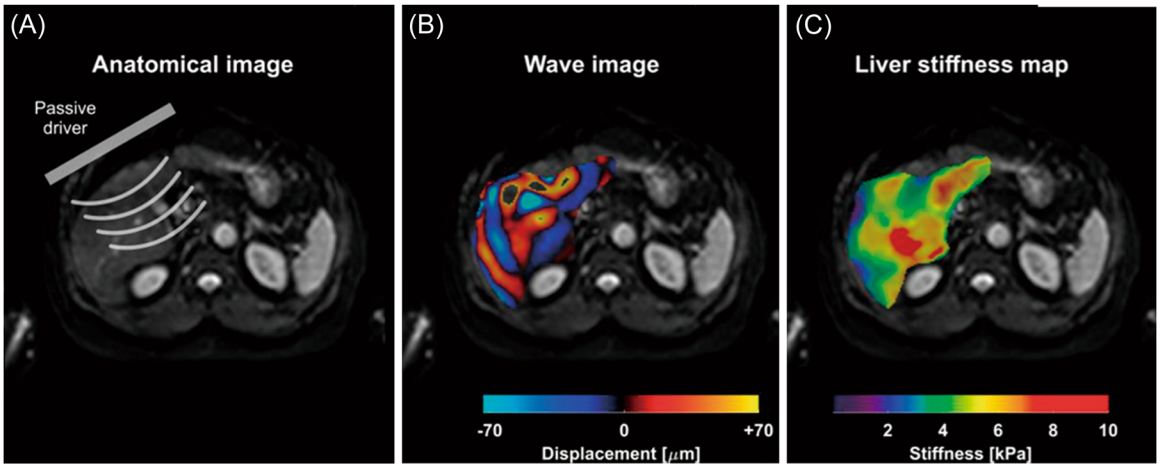

FIGURE 1 To perform MRE a plastic disc (passive driver) is placed on the body surface over the liver. Mechanical waves generated by a shear wave generator that is usually placed outside the scanner room are transmitted through the passive driver into the body and through the liver. A dedicated MRE pulse sequence is then used to image the displacements caused by the propagating mechanical waves. The wavelength of the mechanical shear waves is longer in stiffer tissues and shorter in softer tissues. The wave images are then converted to quantitative stiffness maps that can be analyzed by an image analyst or radiologist. MRE, magnetic resonance elastography.

included 200 patients in which MRE results for 80 patients (16 for each Metavir fibrosis stage) were used to estimate optimal liver stiffness cut-offs to differentiate disease stages, while the results of the remaining 120 patients were used for comparison. The diagnostic accuracy for a liver needle biopsy (52%) was similar to that of MRE (56%) with equivalent overdiagnosis and underdiagnosis rates. The authors used the cut-off value of 4.23 kPa for the diagnosis of cirrhosis with 73% sensitivity.

Lefebvre et al.[50] evaluated the performance of different elastography techniques (TE, pSWE, and MRE) using histopathology as a reference in 100 patients. Technical failure rates were low: 0% for TE, 1% for pSWE, and 6% for MRE, but the per protocol accuracy of MRE was significantly higher than that of TE (0.88 vs. 0.71, $p < 0.05$) and pSWE (0.88 vs. 0.73, $p < 0.05$) for differentiating F0 from ≥F1, and was also significantly higher than of TE for differentiating F0–F1 from F2–F4 (0.85 vs. 0.75, $p < 0.05$).

Similarly, Toguchi et al.[54] compared the MRE and TE in a smaller study of 51 patients. They reported a strongly positive significant correlation between the MRE liver stiffness values and histopathological fibrosis scores ($r = 0.87$, $p < 0.001$) while the association between TE and histopathological scoring was weaker, yet statistically significant ($r = 0.37$, $p < 0.001$).

These results, in addition to findings of other studies comparing MRE and various ultrasound elastography techniques (including VCTE and pSWE) have demonstrated that MRE generally has similar or better performance in the diagnosis of liver fibrosis and cirrhosis.[55–60] MRE has the advantage of being much less operator-dependent compared to ultrasound-based TE, and it can provide a comprehensive evaluation of the liver.[54,61] Moreover, ultrasound elastography techniques are limited by higher failure rates in obese patients or patients with ascites, as well as poor reproducibility.[62,63] On the other hand, MRE is relatively more expensive and could have a limited availability, in addition to the obstacle of patients with contraindications to MRI.[63]

Rustogi et al.[64] and Venkatesh et al.[65] have conducted similar studies, in which they compared the diagnostic performance and assessed the reproducibility of MRE and different anatomic MR imaging features for the detection of severe hepatic fibrosis and cirrhosis, again using histopathology as reference standard. Both shared similar results, in which MRE was demonstrated to be much more reliable, reproducible, and accurate. In the study by Rustogi et al.,[64] three different readers did the evaluation of the scans for the included 72 patients, whereas Venkatesh et al.[65] included 62 patients and 4 radiologists. The anatomical MR imaging features that were studied included liver texture, caudate to right lobe ratios, surface nodularity, signs of portal venous hypertension, among others.

Rustogi et al.[64] combined fibrosis stages F3 and F4 to represent severe fibrosis and cirrhosis, and combined F0–F2 stages to represent lesser stages of fibrosis. Results showed that MRE liver stiffness values >5.9 kPa had average (three readers) sensitivity of 84%, specificity of 88%, and accuracy of 87%; however, Venkatesh et al.[65] used 3.37 kPa as the cut off value for the detection of severe fibrosis; and 5.2 kPa for cirrhosis, with sensitivity, specificity, and accuracy of 100%, 96.5%, and 98.9%; 88.2%, 91.1%, and 93.5%, respectively. The inter-reader agreement for MRE-based stiffness values was excellent in both studies. MRE detected fibrosis in 15.6% of F3–F4 patients in whom no morphological signs of cirrhosis were seen on MRI. There was one MRE false-positive result (congestive cardiac failure).[64]

Compared to MRE, the performance of conventional MRI remained poor. Rustogi et al.[64] reported an overall average sensitivity of 86%, specificity of 56%, and accuracy of 69.3%, and Venkatesh et al.[65] reported results of 48.5%–87.9%, 55.2%–100%, and 71.5%–81.6% for severe fibrosis and 41.2%–82.3%, 64.4%–95.6%, and 60.6%–80.5% for cirrhosis. Moreover, the inter-reader agreement was poor in the study by Rustogi et al.,[64] and poor to good in the study of Venkatesh et al.[65]

27705846, 2022, 1, Downloaded from https://onlinelibrary.wiley.com/doi/10.1002/poh2.6 by Cochrane Canada Provision, Wiley Online Library on [12/12/2023]. See the Terms and Conditions (https://onlinelibrary.wiley.com/terms-and-conditions) on Wiley Online Library for rules of use; OA articles are governed by the applicable Creative Commons License

Among the anatomical features, hepatic nodularity and stigmata of portal hypertension were the best in Rustogi et al.[64] with moderately high overall accuracy of 69.4% and 72.2%, respectively. On the other hand, Venkatesh et al.[65] showed that surface nodularity and overall impression had the best accuracies of 80.3% and 81.6% for the detection of severe fibrosis, whereas for cirrhosis parenchyma texture and overall impression had the best accuracies of 80.5% and 79.7%. It is worth to highlight that MRI imaging features performed better in detecting cirrhosis compared to fibrosis, further emphasizing on their late detection of CLD.

Furthermore, a meta-analysis was done on 910 patients with NAFLD from 12 studies.[66] MRE had an area under the curve (AUC) of 0.95, sensitivity of 0.94, and specificity of 0.75 for the diagnosis of cirrhosis, with the optimal threshold value being 2.74–6.7 kPa, while another similar study of 855 patients showed AUC of 0.90, sensitivity of 0.81, and specificity of 0.90, with the optimal threshold value being 3.35–6.70 kPa.[67] The two studies also showed that MRE had accuracy, sensitivity, and specificity of 0.89, 0.77, and 0.90 for the diagnosis of any fibrosis ($F \geq 1$); 0.93, 0.87, and 0.86 for significant fibrosis ($F \geq 2$); 0.93, 0.89, and 0.84 for advanced fibrosis ($F \geq 3$) in Liang and Li[66] and 0.87, 0.71, and 0.85; 0.91, 0.78, and 0.89; 0.92, 0.83, and 0.89 in Selvaraj et al.,[67] respectively.

These results support the role of MRE for the evaluation of fibrosis and cirrhosis. In addition to the previous studies, Singh et al.[68] highlighted great accuracy of MRE for the diagnosis of the different stages of fibrosis in NAFLD. Xiao et al.[52] also showed that MRE has the highest diagnostic accuracy for staging fibrosis in NAFLD compared to TE and serum tests. Wang et al.[69] showed higher performance of MRE compared to DWI. Loomba et al.[70] showed that 3D MRE at 40 Hz has the highest diagnostic accuracy in diagnosing NAFLD advanced fibrosis compared to 2D MRE and 3D MRE at 60 Hz. It is worth mentioning that the effect of steatosis on liver stiffness values is controversial. Some studies found that patients with steatosis show lower liver stiffness values[71] and more studies have found no significant influence.[50,72,73]

Finally, like other noninvasive tests, MRE can be used for repeated measurements to monitor disease progression, or assess response to management with better patient acceptance.[65] From a health economics point of view, a cost-utility analysis of screening strategies for nonalcoholic steatohepatitis (NASH) showed that MRE was more cost-effective than biopsy.[74] Moreover, Navin et al.[75] highlighted that MRE-based spleen stiffness/liver stiffness ratio can be used to differentiate between nodular regenerative hyperplasia and cirrhosis.

6 | MR IMAGING

Liver MultiScan (Perspectum Ltd.) is the MRI modality most studied for the diagnosis of cirrhosis. The technique evaluates the iron corrected T1 (cT1) as a surrogate of fibrosis and inflammation, T2* as a surrogate of iron accumulation and PDFF as a surrogate of fat content. Iron corrected T1 is the main parameter of interest in the assessment of fibrosis and cirrhosis and is relies on the fact that T1 relaxation time increases with increases in extracellular fluid which are characteristic of fibrosis and inflammation. However, the presence of iron, has a confounding effect. This technology uses iron measurements from T2* maps to remove this confounding effect to produce the iron-corrected T1 (Figure 2A,B).

In the index study describing this technique, Banerjee et al.[77] compared MRI results against liver histopathology. The study included 79 patients with mixed liver disease etiologies. The MR measures correlated strongly with histology with area under the receiver operating curve (AUROC) of 0.94, 0.93, and 0.94 for the diagnosis of any degree of fibrosis, steatosis, and hemosiderosis, respectively. There were significant mean cT1 differences between different Ishak stages, except between mild and moderate fibrosis. The technique showed excellent repeatability in that index study which was also reproduced in a later study.[78]

A subsequent study from the same center examined the performance of liver cT1 in patients with NAFLD and found again promising results.[76] The study involved 71 patients and evaluated the performance of multiparametric MR in the assessment of NASH and fibrosis in those patients using histology as standard. MR data were used to define the liver

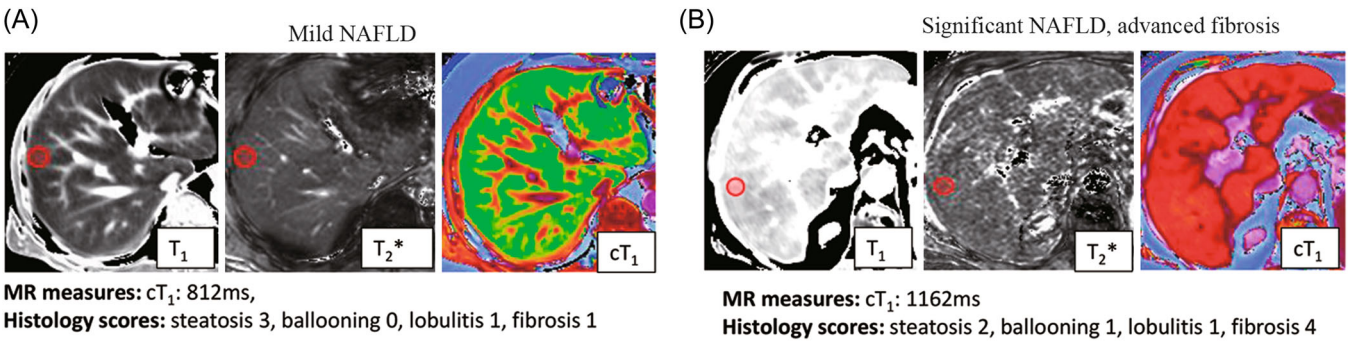

FIGURE 2 Representative MR data produced by Liver MultiScan, adapted from Pavlides 2017.[76] MR data (T1, T2*, cT1 maps) from patients classified using the FLIP algorithm as having: mild disease (A; top panel), and significant disease/advanced fibrosis (B; bottom panel). Regions of interest are indicated by red circles in the T1 and T2* maps. Details of the histology scores are also included. FLIP, fatty liver inhibition of progression; MR, magnetic resonance; NAFLD, nonalcoholic fatty liver disease.

27705846, 2022, 1, Downloaded from https://onlinelibrary.wiley.com/doi/10.1002/poh2.6 by Cochrane Canada Provision, Wiley Online Library on [12/12/2023]. See the Terms and Conditions (https://onlinelibrary.wiley.com/terms-and-conditions) on Wiley Online Library for rules of use; OA articles are governed by the applicable Creative Commons License

inflammation and fibrosis score (LIF 0–4), an early variation of the liver cT1 metric. Histopathology results were classified as NASH or simple steatosis, and mild or significant (activity ≥2 and/or fibrosis ≥2 as defined by the Fatty Liver Inhibition of Progression consortium).

The LIF score (equivalent to liver cT1) had significant associations with histological fibrosis with an AUROC of 0.85 for the diagnosis of cirrhosis. A LIF cut-off of 3.0 showed 91% sensitivity and 73% specificity for the diagnosis of cirrhosis. The study also showed a significant association between histological ballooning grade and the LIF score with an AUROC of 0.83 for the diagnosis of ballooning grades 1 and 2 (vs. no ballooning). A LIF cut-off of 1.2 showed 91% sensitivity and 53% specificity for the diagnosis of ballooning grade >0. For the differentiation of steatosis versus NASH (FLIP algorithm), LIF had an AUROC of 0.80, and a LIF cut-off of 1.4 showed 91% sensitivity and 52% specificity. Lastly, for overall disease severity (mild vs. significant using FLIP), LIF had an AUROC of 0.89, and a LIF cut-off of 1.4 showed 90% sensitivity and 77% specificity.

In an independent cohort of 161 patients from two centers,[79,80] technical failure of MRI was 2.5% with excellent repeatability and reproducibility, and significant inter-scan and inter-subject agreement, with no evidence of a postprandial effect. In the overall patient group, liver cT1 was positively associated with liver fibrosis and had AUC, sensitivity, and specificity of 0.72, 0.71, and 0.64, respectively. Liver cT1 also showed good predictive accuracy for diagnosing significant fibrosis in cases with indeterminate ELF.

Liver MultiScan has now seen more assessments against histology in NAFLD[78,81–85] and other conditions,[86,87] including in clinical trials[78,88] and population studies[89] with further promise.

Other MRI techniques of note that have been investigated for the diagnosis of liver cirrhosis, include the "detection of metabolic liver injury" protocol (deMI-LI)[90] and DWI,[91,92] with varying results and lack of follow-up validation studies to date. For instance, Bonekamp et al.[91] conducted a study on 88 patients and showed that DWI-based liver ADC values were inversely and significantly correlated with fibrosis stage, with accuracy of 78% for detecting cirrhosis. Hoffman et al.[93] compared between the accuracy MRE-based liver stiffness values, T1-based relaxation times, and T2-based relaxation times for the evaluation of liver fibrosis and cirrhosis, and proved that MRE accuracy is superior to both T1 and T2 mapping (AUC: 0.95 vs. 0.7 vs. 0.65, respectively). Dyvorne et al.[59] showed that MRE is superior to DWI for the detection of advanced fibrosis and cirrhosis. Lastly, Lee et al.[92] showed that patients with cirrhosis and with normal renal function have an increased corticomedullary differentiation of both kidneys on axial T1-weighted MRI compared to age-matched controls. Table 1 provides a summary of the studies that examined the diagnostic accuracy of MR technologies for the diagnosis of cirrhosis.

7 | MRI FOR THE ASSESSMENT OF PORTAL HYPERTENSION

The development of portal hypertension is a key event in the natural history of cirrhosis which is associated with serious clinical consequences to patients. These include variceal hemorrhage, hepatic encephalopathy,

TABLE 1 Summary of studies that have examined MR techniques for the diagnosis of cirrhosis.

Modality	Study	Patient group	*N*	Prev F4 (%)	Cut-off	Acc (AUC) (%)	Sens (%)	Spec (%)
MRE	Lefebvre et al.[50]	CLD	100	27	F4 > 2.75 kPa	88	89	63
MRE	Toguchi et al.[54]	CLD	51	8	F4 > 7.86 kPa	90	100	89
MRE	Liang and Li[66]	NAFLD	910	–	F4 > 2.74–6.7 kPa	95	94	75
MRE	Selvaraj et al.[67]	NAFLD	855	5	F4 > 3.35–6.70 kPa	90	81	90
MRE	Rustogi et al.[64]	CLD	72	39	F3–F4 > 5.9 kPa	87	85	88
MRE	Venkatesh et al.[65]	CLD	62	28	F4 > 5.2 kPa	93	88	91
MRE	Singh et al.[68]	CLD	697	30	F4 > 4.71 kPa	92	91	81
MRE	Loomba et al.[70]	NAFLD	117	9	F3–F4 > 3.63 kPa	93	86	91
MRI	Dyvorne et al.[59]	CLD	60	18	-MRE: F3–F4 > 4.07 kPa	–94	–92	–92
					-DWI: F3–F4 < 0.92 (D)	–79	–67	–85
					-DCE: F3–F4 > 11.5 (MTT)	–79	–80	–72
cT1	Pavlides et al.[76]	NAFLD	71	15	F4 > 3.0 LIF	85	91	73
cT1	McDonald et al.[79]	CLD	161	12%	-MIS 5–6 > 950 ms (cT1)	72	71	64
					-MIS 5–6 > 3 LIF			
DWI	Bonekamp et al.[91]	CLD	88	31	F4 > 1.30 (ADC)	78	87	63

Abbreviations: ADC, apparent diffusion coefficient; AUC, area under the curve; CLD, chronic liver disease; cT1, iron corrected T1; D, diffusion coefficient; DCE, dynamic contrast-enhanced MRI; DWI, diffusion-weighted imaging; F4, metavir fibrosis score 4; LIF, liver inflammation and fibrosis score; MIS, modified Ishak score; MR, magnetic resonance; MRE, magnetic resonance elastography; MTT, mean transit time; NAFLD, nonalcoholic fatty liver disease.

27705846, 2022, 1, Downloaded from https://onlinelibrary.wiley.com/doi/10.1002/poh2.6 by Cochrane Canada Provision, Wiley Online Library on [12/12/2023]. See the Terms and Conditions (https://onlinelibrary.wiley.com/terms-and-conditions) on Wiley Online Library for rules of use; OA articles are governed by the applicable Creative Commons License

ascites, and renal dysfunction.[94,95] The most reliable method to assess portal pressure in patients with cirrhosis is the measurement of the hepatic venous pressure gradient (HVPG) through hepatic vein catheterization,[96] in which normal HVPG values are between 3 and 5 mmHg. Patients with HVPG values >5 mmHg are considered to have portal hypertension while the diagnosis of clinically significant portal hypertension (CSPH) is made when the HVPG values are ≥10 mmHg.[95]

This process of portal hypertension assessment and grading is of great value for patients with cirrhosis. First, it is helpful to risk-stratify patients based on the level of their portal pressure and identifies patients who are more likely to have a worse course.[95,97] It was illustrated that HVPG levels >10 mmHg predicts more likelihood of PH complications to appear (including esophageal varices [EV], ascites, and hepatic encephalopathy) in addition to postsurgical decompensation, while HVPG >12 mmHg identifies variceal bleeding risk, and HVPG >16 mmHg is associated with higher risk of death.[95,98] Furthermore, portal pressure measurement has been implicated as a part of ideal clinical management, as goals of therapy differ along the spectrum of HVPG values, which is reflected as different stages and substages of cirrhosis.[95] The reason behind this is the difference in mechanisms maintaining the PH along this spectrum of HVPG and cirrhosis substages, thus different therapeutic approach should be utilized.[95] For instance, a recent multicenter randomized controlled trial showed that treatment with β-blockers once CSPH (HVPG >10 mmHg) is detected, regardless of the existence of EV, has reduced decompensation and liver-related death.[99] Another treatment-related application of portal pressure monitoring is the ability to explore therapy efficacy and patient responsiveness by performing pre-therapy and post-therapy HVPG measurements.[97] For example, patients who achieve a portal pressure of 12 mmHg or less or achieve an HVPG reduction of at least 20% from baseline when given nonselective β-blockers are at reduced risk of recurrent variceal hemorrhage, ascites, and death.[95,97,100]

Despite the previous prognostic and therapeutic value of portal pressure assessment and monitoring, HVPG measurements are invasive, relatively expensive, not widely available, and require specific expertise, which has limited the assessment of HVPG.[95] Also, routine monitoring of HVPG changes has been discouraged by guidelines, unless if part of clinical trials, especially those investigating novel therapies.[97] This situation made the development of noninvasive surrogate markers of portal pressure, and predictors of HVPG highly desirable. In this section, we review and compare MRI modalities utilized to assess portal hypertension among cirrhosis patients.

7.1 | MRE

Ultrasound-based elastography methods, including ultrasound-based vibration-controlled transient elastography (VCTE; Fibroscan, Echosens), exhibited a good diagnostic accuracy to detect CSPH and correlated well with HVPG in multiple studies.[101–103] Despite being rapid noninvasive techniques, they are limited by operator dependence, unreliability in patients with ascites or obesity and having a small sampling window.[62] MRE is an alternative for measuring liver and spleen stiffness among other viscoelastic parameters. Because the entire liver and spleen are scanned, MRE provides a measurement of stiffness in larger areas, making it theoretically superior to ultrasound-based elastography methods.[100] Furthermore, MRE can be successfully performed in most patients, including those with ascites, anatomical variants, and liver transplant recipients.[104]

Wagner et al.[105] assessed MRE measured liver stiffness and spleen stiffness among 34 patients with CLD. Fifty percent of the patients had histologically proven advanced fibrosis/cirrhosis. Liver stiffness showed a significantly moderate correlation with HVPG ($r = 0.486$, $p = 0.006$) while spleen stiffness did not show any significant correlation ($r = 0.099$, $p = 0.714$). Liver stiffness measures were significantly different between the group of patients with/without PH and CSPH, in which AUROC analysis of liver stiffness to detect PH and CSPH was 0.809 and 0.742, respectively. Conversely, spleen stiffness measures did not significantly differ between the groups with/without PH and PH. Another study by Gharib et al.[106] explored the liver shear wave velocity, a measure of liver stiffness. The study sample consisted of 23 patients with advanced liver disease having related to human immunodeficiency virus (HIV), hepatitis C virus (HCV), or HIV/HCV. Forty-eight percent had histologically proven cirrhosis and MRE was done in 15 patients. They reported a significant correlation between shear wave velocity and HVPG ($r = 0.64$, $p = 0.009$) by Spearman correlations, and shear wave velocity was independently associated with HVPG on multivariate regression analysis ($R^2 = 0.377$, $p = 0.02$). These previous studies highlight the ability of MRE-measured liver stiffness to predict HVPG and identify CSPH.

Ronot et al.[107] assessed liver and spleen viscoelastic parameters by multifrequency MRE among 36 patients with cirrhosis. Parameters included: the complex-valued shear, storage, and loss moduli (G*, Gd, and Gl, respectively [kPa]). The liver storage and loss moduli and the spleen shear, storage, and loss moduli correlated significantly with the HVPG by Spearman correlations, however, only the liver and the spleen loss modulus significantly correlated with the HVPG at multiple regression ($r = 0.44$, $p = 0.017$, and $r = 0.57$, $p = 0.002$, respectively). In contrast to findings of Wagner et al.,[105] all liver viscoelastic parameters did not significantly differ between patients with/without CSPH, whereas the spleen G*, Gd, and Gl were significantly higher in patients with severe portal hypertension (defined as HVPG >12 mmHg). Spleen viscoelastic parameters AUROCs analysis to detect severe PH ranged from 0.73 to 0.81 with the spleen loss modulus being the best of them ($p = 0.019$, AUROC = 0.81).

Ronot et al.[107] discussed how other confounding factors, besides the effects of portal hypertension, can

27705846, 2022, 1, Downloaded from https://onlinelibrary.wiley.com/doi/10.1002/poh2.6 by Cochrane Canada Provision, Wiley Online Library on [12/12/2023]. See the Terms and Conditions (https://onlinelibrary.wiley.com/terms-and-conditions) on Wiley Online Library for rules of use; OA articles are governed by the applicable Creative Commons License

influence liver stiffness measurements such as the presence of extensive hepatic fibrosis and the variation in the underlying cirrhosis-causing disease, which could explain why spleen viscoelastic parameters had superior diagnostic performances when compared to the liver parameters in their study.[58,108] Wagner et al.[105] stated that using a one-directional MRE to assess the spleen stiffness instead of the three-directional MRE used by Ronot et al.[107] could explain why spleen stiffness measurements were not able to accurately identify patients with PH. The one-directional MRE sequence was designed for the liver and three-directional MRE has been suggested to be more appropriate for spleen anatomy.[105,109]

Regarding the assessment of gastroesophageal varices (GEV), MRE methods have been explored by various studies. Matsui et al.[110] demonstrated a significant ability of MRE to predict the detection of varices during endoscopy (AUC = 0.85) with a sensitivity and specificity of 85% and 69%, respectively, which improved in the validation cohort to reach 90% and 71%. Hoffman et al.[111] found a significant moderate correlation between MRE measured liver stiffness and the presence of varices on endoscopy ($r = 0.28$ and 0.30) with an excellent ability to predict varices on endoscopy (AUC was 0.923 and 0.873 for each of the readers). Similarly, Sun et al.[112] reported a well correlation between MRE measured liver stiffness and the grade of EV ($r = 0.63$), with AUC values to predict the presence of varices and high-risk varices (Grade II) as 0.859 and 0.810, respectively.

In addition to previous promising results of MRE-measured liver stiffness, Shin et al.[109] reported that MRE-measured spleen stiffness also correlated with grade of GEV and had good ability to predict varices (AUC = 0.821) and high-risk varices (0.750). Ronot et al.[107] also exhibited an excellent ability of splenic loss modulus (Gl) to identify high-risk varices (AUC = 0.93), but with 54% sensitivity.

Sun et al.[112] discussed integrating MRE into the evaluation process of cirrhotic patients as a method to suggest the need for endoscopy, but not as its replacement. This would have multiple advantages as MRE is noninvasive, less bothering to patients, and can contribute to the diagnosis of accompanying liver parenchymal disorders or other liver cirrhosis-related complications including HCC[112] which will enhance patient care. Collectively, previously mentioned studies point toward a good potential for MRE to be incorporated into the management plan of cirrhotic patients in terms of GEV detection.

7.2 | MRI measured T1 (longitudinal) or T2 (transverse) relaxation times and other mapping techniques

The performance of various MRI relaxometry measurements to correlate with the degree of fibrosis has been examined by various studies.[113,114] Recently, researchers have investigated the correlation of several liver and spleen relaxometry measurements with portal hypertension. Levick et al.[115] have developed a multiparametric MR technique that can be used to measure the "iron corrected T1 relaxation time" (cT1)[11] and explored the correlation of liver and spleen cT1 with HVPG in their "*proof of concept*" study. Spleen cT1 had a significant correlation with HVPG ($r = 0.69$; $p = 0.001$) while liver cT1 did not significantly correlate with HVPG ($r = 0.40$; $p = 0.101$). Only spleen cT1 was identified as an independent predictor of HVPG on multivariate regression ($p = 0.03$). Spleen cT1 had excellent accuracy to diagnose PH and CSPH with AUROC of 0.92 ($p = 0.002$) for both, while liver cT1 showed significant accuracy for the diagnosis of CSPH only with AUROC of 0.81 ($p = 0.026$). Another study supporting the utility of spleen relaxometry methods is the study by Hectors et al.,[116] which have assessed liver and spleen T1ρ (T1rho) in addition to basic liver and spleen T1. T1ρ is sensitive to the interactions between water molecules and macromolecules, including collagen[117,118] which made the authors consider utilizing it to better capture the pathophysiological changes of PH in both the liver and spleen.[116] Among all relaxometry parameters, only spleen T1ρ significantly correlated with HVPG ($r = 0.613$, $p = 0.001$) and demonstrated a significant ability to detect PH (0.817, $p = 0.015$) and CSPH (0.778, $p = 0.024$). Authors suggested that the better performance of spleen relaxometry measurements when compared to hepatic measurements could be related to possible cofounders preventing accurate hepatic assessment such as hepatic iron deposition and inflammation.[116,119] Furthermore, the large variability in pathophysiological characteristics between liver diseases may introduce inaccuracies when compared with the pathophysiological changes of PH in the spleen that may be less influenced by differences in disease etiology.

Palaniyappan et al.[120] have explored the liver T1 in addition to liver and spleen apparent recovery time (T1*) obtained from a balanced steady-state free precession (bSSFP) readout scheme. Liver T1 correlated significantly with HVPG (Pearson $R = 0.835$, $p < 0.001$) which remained significant in the multivariate model. Also, liver T1* correlated significantly with HVPG (Pearson $R = 0.780$, $p < 0.001$) for HVPG >5 mmHg, while spleen T1* did not correlate significantly with HVPG in patients with PH or CSPH. Mesropyan et al.[121] have reported no significant correlation between any splenic or hepatic, T1 or T2 parameters, and HVPG. However, hepatic T1 (native) demonstrated a significant ability to diagnose CSPH with an AUROC of 0.926. Splenic T1 (native) followed with an AUROC of 0.806. Finally, Wagner et al.[105] reported that liver and spleen T1 did not have a statistically significant correlation with HVPG and did not have a significant ability to diagnose CSPH.

Discrepancies in the performance of hepatic T1 measurements between studies have been related to previously mentioned variabilities in underlying pathologies, in addition to variable hepatic iron and fat content which may affect the T1 quantification.[113] Furthermore, variations in the contrast dose, renal clearance rate, scanning time, body composition, and hematocrit levels among the sample could have contributed to some discrepancies in post-contrast T1

27705846, 2022, 1, Downloaded from https://onlinelibrary.wiley.com/doi/10.1002/poh2.6 by Cochrane Canada Provision, Wiley Online Library on [12/12/2023]. See the Terms and Conditions (https://onlinelibrary.wiley.com/terms-and-conditions) on Wiley Online Library for rules of use; OA articles are governed by the applicable Creative Commons License

results among studies.[121] MRI relaxometry techniques have good potential, but It is difficult to draw conclusive conclusions regarding the best mapping method at the moment. Spleen relaxometry measures may be more consistent due to less covariables, especially when a rigorous technique is employed, but further studies are needed to validate proposed methods such as splenic cT1 and T1ρ and to choose the most suitable and practical technique.

Concerning the usage of MRI relaxometry measurements as predictors of GEV, Hoffman et al.[111] have studied the ability of T1 and T2 relaxation times to predict the detection of GEV upon endoscopy. T1 relaxation time had a significant ability to detect varices, with AUC values of 0.711 ($p = 0.004$) and 0.675 ($p = 0.010$) for both readers, respectively. In contrast, T2 relaxation time was not a significant predictor of GEV.[111]

7.3 | Blood vessel flow parameters

Many hemodynamic changes accompany cirrhosis, including the increased splanchnic inflow with the decreased portal flow to the liver due to increasing sinusoidal resistance and the development of portosystemic collaterals.[122,123] The value of several flow parameters has been assessed by Doppler ultrasound in diagnosis and grading of PH and liver dysfunction extent among cirrhosis patients.[124,125] However, there is still no standardized parameter and validated method to be used for that purpose, which is mostly due to the reported high intra- and interobserver variability and observer dependency of Doppler US.[123–125]

Azygous flow parameters have shown a successful correlation with HVPG in several studies.[120,126] Authors have discussed how the azygous flow could "mirror" the amount of gastroesophageal collaterals development as these collaterals drain into the azygous system.[126–128] Also, one study found a correlation between superior mesenteric artery (SMA) flow parameters and HVPG, which could reflect the hyperdynamic state in portal hypertension.[120] Further studies are needed before adoption of any specific parameter to validate findings and explore best techniques.

As of the ability of flow parameters to predict GEV, several studies have assessed different flow variables in this context. The most assessed technique to obtain the flow measurements was the phase-contrast MRI (PC-MRI). Gouya et al.[129] demonstrated that the ability of the PC-MRI-based mean azygos flow, to diagnose Grade 2 or higher varices (AUC = 0.90) was significantly better than that of either mean portal venous flow or mean aortic flow (AUC = 0.43, 0.66, respectively). Similarly, the mean azygous flow highly and significantly correlated with varix grade, unlike mean portal venous flow and mean aortic flow.[129] Wu et al.[130] have found that cirrhotic patients with azygous time-averaged velocity > 15 cm/s may have higher risk of variceal hemorrhage. High PC-MRI measured portal flow could be associated with variceal hemorrhage,[131] but as mentioned previously, it does not seem to perform well when compared to azygous flow in terms of correlation with varices grading.[129] Mean velocity, cross-sectional area, and flow volume within the superior mesenteric vein (SMV) were not significantly able to detect or stratify GEV.[132]

Another newly investigated technique was the four-dimensional (4D) flow MRI which enables for the assessment of the vascular tree (including collaterals) in addition to quantifying and detecting alterations in blood flow.[133,134] Motosugi et al.[135] used the 4D-flow MRI to create angiograms to measure flow volumes in main portal vein (PV), SMV, splenic vein, and azygos vein among patients with liver cirrhosis. Flow volume in the azygos vein >0.1 L/min ($p = 0.034$) and fractional flow change in the PV of <0 ($p < 0.001$) were independent indicators of varices at high risk of bleeding. 4D-flow MRI does not require double oblique acquisition planes which makes the data acquisition process simpler than the 2D PC-MRI; however, the postprocessing time may take about 30–60 min/patient.[135] This problem may be solved upon automation of the analysis in the future.[135]

7.4 | Gadoxetate DCE MRI parameters

A recent study by Hectors et al.[136] assessed the correlation between gadoxetate DCE-MRI parameters of the liver and spleen and HVPG among 35 patients with CLD, and the diagnostic performance of these parameters to predict PH and CSPH was demonstrated. Liver uptake fraction (f_i) and uptake rate (k_i) both showed a significant negative correlation with HVPG ($r = -0.482$, $p = 0.003$ and $r = -0.490$, $p = 0.003$, respectively). In terms of spleen parameters, extravascular extracellular volume fraction (v_e) showed a significant positive correlation with HVPG ($r = 0.336$, $p = 0.048$). Among all explored parameters, only hepatic f_i, hepatic k_i, and splenic v_e exhibited significant ability to diagnose PH and/or CSPH with the cut-off points, sensitivity, and specificity summarized in Table 2. Authors have found that the best classifier for the diagnosis of CSPH was, in fact, the combination of liver k_i and spleen v_e with an AUC, sensitivity, and specificity of 0.87, 100%, and 73.1%, respectively.[136] These findings are promising but require validation in an independent cohort.

7.5 | Liver surface nodularity (LSN) assessment

Given that LSN increases with increasing cirrhosis severity, researchers have developed several software programs to quantify LSN from radiographic images.[139,140] The first program used CT scan for the detection and evaluation of cirrhosis, which have demonstrated that it could allow the detection of CSPH and prediction of decompensation events and death in patients with cirrhosis.[141,142] Liu et al.[137] performed LSN quantification using noncontrast-enhanced MRI, and have developed the CHESS-DIS Score (see also Figure 3). Sample included 149 patients with cirrhosis divided into 124 from Chinese hospitals "training

27705846, 2022, 1, Downloaded from https://onlinelibrary.wiley.com/doi/10.1002/poh2.6 by Cochrane Canada Provision, Wiley Online Library on [12/12/2023]. See the Terms and Conditions (https://onlinelibrary.wiley.com/terms-and-conditions) on Wiley Online Library for rules of use; OA articles are governed by the applicable Creative Commons License

TABLE 2 MR techniques for the detection of PH and CSPH.

Modality	Study	Patient group	*n*	Cut-off (measured variable)	Sensitivity/specificity for target condition	AUC
Magnetic resonance elastography	Wagner et al.[105]	CLD	34	3.01 kPa (LSM)	85%/73% for PH	0.809
				5.75 kPa (LSM)	55%/91% for CSPH	0.742
	Ronot et al.[107]	Cirrhosis	36	4.5 kPa (spleen Gd)	65%/85% for severe PH (HVPG 12 mmHg)	0.81
				2.5 kPa (spleen Gl)	64%/92% for severe PH (HVPG 12 mmHg)	0.81
cT1	Levick et al.[115]	Suspected cirrhosis (10 with cirrhosis)	19	1282 ms (spleen cT1)	91%/88% for PH	0.92
				1376 ms (spleen cT1)	89%/100% for CSPH	0.92
						0.81
				909 ms (liver cT1)	88%/70% for CSPH	
T1	Hectors et al.[116]	CLD (14 with cirrhosis)	25	90.2 (spleen T1)	94%/57% for PH	0.82
				114.7 (spleen T1)	67%/94% for CSPH	0.78
Gadoxetate DCE-MRI	Hectors et al.[136]	CLD (13 with cirrhosis)	35	5.7 (liver k_i, 100/min)	71.4%/78.6% for PH	0.741
				5.4 (liver k_i, 100/min)	88.9%/65.4% for CSPH	0.774
				8.1% (liver f_i)	61.9%/85.7% for PH	0.735
				7.3% (liver f_i)	77.8%/84.6% for CSPH	0.825
				39.9% (spleen v_e)	100%/50.0% for CSPH	0.799
T1	Mesropyan et al.[121]	Cirrhosis patients and healthy volunteers (33 with cirrhosis) (50 in total, 40 in derivation cohort and 10 in validation cohort)	50	569 ms (hepatic T1, native)	92.9%/91.7% for CSPH (derivation)	0.926 (derivation)
				1060 ms (splenic T1, native)	100%/100% for CSPH (validation)	0.806 (derivation)
				42.60 ms (hepatic T2)	74.1%/91.7% for CSPH (derivation)	0.731 (derivation)
					100%/80.0% for CSPH (validation)	0.736 (derivation)
				115 ms (splenic T2)	85.7%/58.3% for CSPH (derivation)	
					100%/40% for CSPH (validation)	
					46.4%/100% for CSPH (derivation)	
					40.0%/100% for CSPH (validation)	

27705846, 2022, 1, Downloaded from https://onlinelibrary.wiley.com/doi/10.1002/poh2.6 by Cochrane Canada Provision, Wiley Online Library on [12/12/2023]. See the Terms and Conditions (https://onlinelibrary.wiley.com/terms-and-conditions) on Wiley Online Library for rules of use; OA articles are governed by the applicable Creative Commons License

TABLE 2 (Continued)

Modality	Study	Patient group	*n*	Cut-off (measured variable)	Sensitivity/specificity for target condition	AUC
2D-cine PC-MRI	Gouya et al.[126]	Cirrhosis	69	4.4 ml/s (azygous flow)	92%/94% for severe PH (16 mmHg)	0.96
LSN quantification (noncontrast-enhanced MRI)	Liu et al.[137]	(1) Training cohort (cirrhosis)	124	6.94 (CHESS-DIS score)	57%/95% for CSPH	0.81
		(2) Validation cohort (cirrhosis)	25	6.08 (CHESS-DIS score)	92%/92% for CSPH	0.91
LSN quantification (Gd-BOPTA-enhanced MRI)	De Vos et al.[138]	Cirrhosis	30	2.24 (T1-wPVP based LSN score)	85.7%/78.6% for CSPH	0.801
				2.23 (T1-wHBP based LSN score)	92.3%/76.9% for CSPH	0.876
				2.52 (T2-w based LSN score)	73.3%/92.3% for CSPH	0.823

Abbreviations: CLD, chronic liver disease; CSPH, clinically significant portal hypertension; cT1, iron corrected T1; DCE-MRI, dynamic contrast-enhanced magnetic resonance imaging; f_i, uptake fraction; Gd, storage modulus; Gd-BOPTA, gadobenic acid; GI, loss modulus; HVPG, hepatic venous pressure gradient; k_i, uptake rate (100/min); LSM, liver stiffness measurement; LSN, liver surface nodularity; MR, magnetic resonance; PC-MRI, phase-contrast magnetic resonance imaging; PH, portal hypertension; PV, portal vein; SS, splenic stiffness; T1ρ, T1rho; T1-wHBP, T1-weighted hepatobiliary phase; T1-wPVP, T1-weighted portal venous phase; T2-w, T2-weighted; v_e, extravascular extracellular volume fraction.

cohort" and 25 from international hospitals "validation cohort." Interestingly, CHESS-DIS score correlated with HVPG ($r = 0.36$, $p < 0.001$ and $r = 0.55$, $p < 0.01$) for the training and validation cohorts, respectively. Furthermore, the AUROC value of CHESS-DIS score to detect CSPH was 0.81 and 0.9 in the training and validation cohorts, respectively.[137] Another study by De Vos et al.[138] performed LSN quantification using Gd-BOPTA-enhanced MRI through a score derived from either axial T2-, T1-weighted (portal venous phase) PVP, or T1-weighted hepatobiliary phase (HBP). All LSN scores have correlated with HVPG and the AUROC values of the LSN scores to detect CSPH were (T1-wPVP = 0.876; T1-wHBP = 0.823; T2-w = 0.801). Both studies, despite different approaches to quantify LSN, point toward a promising potential of MRI quantified LSN to diagnose and stage portal hypertension. Current data suggest that the performance of MRI-based quantification of LSN is comparable to CT-based methods, which could be in the favor of using MRI, as MRI studies are frequently performed in patients with cirrhosis and will make patients avoid unnecessary radiation exposure.[138]

Tables 2 and 3 provide a summary of the techniques used for the assessment of portal pressure and EV.

7.6 | MRI to assess portal vein thrombosis (PVT)

Many conditions including cirrhosis, neoplastic diseases, myeloproliferative disorders, and hypercoagulable states could cause the formation of PVT.[143] Cirrhosis is the most common cause of benign PVT in adults, and cirrhotic patients may develop either benign or malignant PVT.[144,145] In some situations, benign and malignant thrombi can coexist.[146] The utility of MRI in the assessment of cirrhosis-related PVT has been explored by several studies under the general idea of depending on MRI modalities to distinguish between benign and malignant PVTs. This has a critical implication for prognosis and therapeutic approach to patients, in which malignant PVT is an absolute contraindication to liver transplant, and its presence worsens prognosis while benign PVT does not have the same high levels of morbidity and can potentially be treated with anticoagulation.[147,148]

Three studies exploring the usage of diffusion-weighted MRI (DWI) to discriminate benign and malignant PVTs have shown contradictory results. Catalano et al.[149] suggested that DWI enabled successful discrimination between both types of thrombi through a difference of apparent diffusion coefficient (ADC) parameters, however, the other two studies by Ahn et al.[150] and Sandrasegaran et al.[151] reported that DWI could not efficiently distinguish between both types of PVTs, and that ADC parameters were not significantly different between benign and malignant PVTs. This has decreased enthusiasm toward utility of DWI for this purpose and future studies may determine the cause of these study differences.

Of great importance, a recent study by Gawande et al.[147] illustrates how post-contrast and subtraction

27705846, 2022, 1, Downloaded from https://onlinelibrary.wiley.com/doi/10.1002/poh2.6 by Cochrane Canada Provision, Wiley Online Library on [12/12/2023]. See the Terms and Conditions (https://onlinelibrary.wiley.com/terms-and-conditions) on Wiley Online Library for rules of use; OA articles are governed by the applicable Creative Commons License

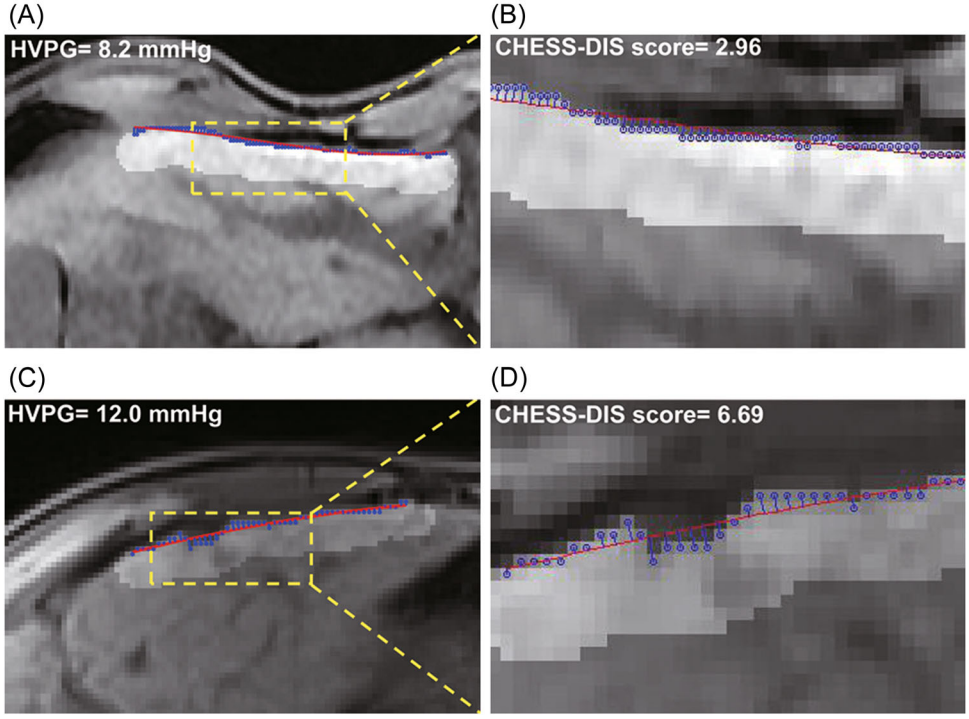

FIGURE 3 Sample images from the study by Liu et al.[137] from a patient without CSPH in (A) and another with CSPH in (C). (B and D) illustrate how the liver edge irregularity is quantified by measuring the distance of the actual liver edge to the predicted smooth liver edge (red line) at multiple points (blue dots/lines). CSPH, clinically significant portal hypertension; HVPG, hepatic venous pressure gradient.

MRI can reliably distinguish malignant from benign PVT in patients with HCC, by using subtracted or nonsubtracted images at arterial, portal venous, or delayed phase timing. These findings will definitely pull the attention toward future efforts to validate these results and select best quantified measure.

8 | MRI FOR THE PREDICTION OF CLINICAL OUTCOMES

The natural history of cirrhosis is characterized by a long asymptomatic phase or compensated cirrhosis phase. If the underlying disease etiology is unchecked then the disease can progress to become decompensated in a state where patients develop complications like ascites, variceal bleeding, or hepatic encephalopathy. The rate of decompensation is about 5%–7%/year.[152] Predicting which patients will progress to develop decompensation is challenging in clinical practice and one area where quantitative liver MR biomarkers have been examined.

8.1 | MRE

Most of the available data for predicting outcomes in patients with the liver disease come from studies that have examined MRE. In a retrospective study in patients with liver cirrhosis due to mixed etiologies, Asrani et al.[153] showed that liver stiffness measured by MRE was associated with decompensation at baseline. In those with compensated disease at baseline an MRE liver stiffness ≥5.8 kPa conferred a higher risk of decompensation over a median follow-up of 27 months. One strength observed in this study was that researchers were able to use MRE in patients who are obese, and still were able to gather data with low rates of incompletion. Furthermore, in this study, the association between elevated liver stiffness and decompensation was independent of ALT as a potential reflection of confounding from inflammation.

In a similar retrospective study of 217 patients with compensated disease from Korea, Lee et al.[154] found similar results with MRE liver stiffness having significant association with future decompensating events with a hazard ratio (HR) of 2.02 per unit increase in liver stiffness. A cut-off of 4.44 kPa was identified as conferring a higher risk of HCC and a similar cut-off on 4.46 kPa for a higher risk of decompensation. One weakness observed in this study was that iron could potentially be a limitation for MRE with the sequence that was used in this study in predicting the degree of liver fibrosis.

The results of these two early studies were reproduced in a more recent retrospective study of 1269 patients.[155] In this study, MRE liver stiffness predicted the development of cirrhosis in those without cirrhosis at baseline (HR: 2.38; $p < 0.0001$), decompensation in those with compensated disease at baseline (HR: 1.22; $p < 0.0001$), and liver transplantation or mortality in those with decompensation at baseline (HR: 1.11; $p = 0.013$), but the latter was not independent of MELD score or Child Pugh stage.

The predictive value of MRE for future events has also been examined in disease-specific cohorts. In a retrospective multicentre study of 320 patients with NAFLD,[156] MRE liver stiffness was associated with decompensation and mortality, although it is not clear

27705846, 2022, 1, Downloaded from https://onlinelibrary.wiley.com/doi/10.1002/poh2.6 by Cochrane Canada Provision, Wiley Online Library on [12/12/2023]. See the Terms and Conditions (https://onlinelibrary.wiley.com/terms-and-conditions) on Wiley Online Library for rules of use; OA articles are governed by the applicable Creative Commons License

TABLE 3 MR techniques for the detection of gastroesophageal varices.

Modality	Study	Patient group	*n*	Cut-off (measured variable)	Sensitivity/specificity (target condition)	AUC
Magnetic resonance elastography	Matsui et al.[110]	(1) Estimation cohort (CLD)	272	>4.2 kPa (LSM)	85%/69% (to identify varices on endoscopy)	0.85
		(2) MRE validation cohort (CLD)	243	>4.2 kPa (LSM)	90%/71% (to identify varices on endoscopy)	Not reported
	Hoffman et al.[111]	Known or suspected hepatic fibrosis	223	>4.5 kPa (LSM)	79.4%/85.2% (to identify varices on endoscopy)	0.923/0.873 (readers 1/2)
	Shin et al.[109]	Cirrhosis	139	>4.58 kPa (LSM)	85.9%/72.1%	0.821
				>7.23 kPa (SS)	84.6%/78.7% (to identify varices on endoscopy)	0.833
	Sun et al.[112]	Cirrhosis	126	>4.63 kPa (LSM)	Not reported (to identify varices on endoscopy)	0.859
				>5.80 kPa (LSM)	96%/60% (to identify high grade (≥II) varices)	0.810
	Ronot et al.[107]	Cirrhosis	36	>4.2 kPa (splenic Gl)	54%/100% (to identify high risk varices[a])	0.93
T1	Hoffman et al.[111]	Known or suspected hepatic fibrosis	223	>783 ms (T1)	58.8%/68.6% (to identify varices on endoscopy)	0.711/0.675 (readers 1/2)
4D-flow	Motosugi et al.[135]	Cirrhosis	23	>0.1 L/min (azygous vein flow volume)	100%/62% to (identify high risk varices[a])	Not reported
				<0 (fractional flow change in PV)	100%/94% to (identify high risk varices[a])	Not reported
PC-MRI	Gouya et al.[129]	(1) Cirrhosis	59	>2.3 ml/s (mean azygous flow)	89%/80% (to identify high grade (≥II) varices among all patients)	0.90
		(2) CLD	12			
		(3) NRH	11			
		(4) Healthy	25			

Abbreviations: CLD, chronic liver disease; Gl, loss modulus; LSM, liver stiffness measurement; MR, magnetic resonance; PC-MRI, phase-contrast magnetic resonance imaging; PV, portal vein; SS, splenic stiffness.

[a]High-risk esophageal varices were defined according to the Baveno V criteria as grade II to III varices or grade I varices with red color signs or Child-Pugh class C.

whether decompensation was present at baseline or developed during follow-up. Furthermore, the median follow-up between MRE and development of clinical events was only 7.4 months, suggesting that patients may have been decompensated at baseline. A cross-sectional study was also shown an association between liver stiffness and cardiovascular disease in patients with NAFLD.[157]

In patients with primary biliary cholangitis, an MRE liver stiffness cut-off of 4.30 kPa predicted decompensation after a median follow-up of 2.24 years and remained significant after adjusting for response to ursodeoxycholic acid (HR, 1.68; 95% confidence interval [95% CI], 1.28–2.19) and GLOBE score (HR, 2.09; 95% CI, 1.57–2.78).[158] Similarly, a cut-off of 4.32 kPa was found to be predictive of outcomes in patients with primary sclerosing cholangitis,[159] while the latter study also found that in patients who developed decompensation the rate of liver stiffness increase was higher than those who remained compensated (0.6 kPa/year vs. −0.04 kPa/year; $p < 0.001$).

While the accumulating MRE data show promise for the predictive value of this technique, they are mainly from retrospective studies with no independent validation of pre-specified cut-offs. The cut-offs that have been identified though are similar in the studies and this would offer motivation to select a pre-specified value to be validated in future studies.

8.2 | Multiparametric MRI

Beyond MRE, multiparametric MRI is the only other notable technique that has been examined for the prediction of clinical outcomes in patients with liver disease. The studies by Pavlides et al.[160] and Jayaswal et al.[161] examined Liver MultiScan (Perspectum Ltd.) in a cohort of patients with liver disease of mixed etiology and varying severity. The first study[160] examined 123 patients over a median follow-up of 27 months while the more recent study[161] evaluated an expanded cohort of 197 patients over a longer follow-up (median 43 months;

27705846, 2022, 1, Downloaded from https://onlinelibrary.wiley.com/doi/10.1002/poh2.6 by Cochrane Canada Provision, Wiley Online Library on [12/12/2023]. See the Terms and Conditions (https://onlinelibrary.wiley.com/terms-and-conditions) on Wiley Online Library for rules of use; OA articles are governed by the applicable Creative Commons License

TABLE 4 MR techniques for the prediction of clinical outcomes.

Modality	Study	Patient group	*n*	Follow-up length	Cut-off
Magnetic resonance elastography	Asrani et al.[153]	cCLD	167	Median 27 months	≥5.8 kPa increased risk of decompensations
	Lee et al.[154]	cCLD	217	Mean 45 months	>4.44 kPa: increased risk of HCC >4.46 kPa increased risk of decompensation
	Gidener et al.[155]	(1) No cirrhosis	821	7.8 years	Baseline LSM predicted development of cirrhosis in (1), decompensation in (2), and mortality/transplant in (3)
		(2) Cirrhosis	277	10.2 years	
		(3)Decompensated	171	12 years	
	Han et al.[156]	NAFLD	320		>6.48 kPa associated with decompensation at baseline
	Osman et al.[158]	PBC	332	2.24 years	>4.3 kPa higher risk of decompensation
	Eaton et al.[159]	PSC	204	Median 4 years	>4.32 kPa higher risk of decompensation
cT1	Jayaswal et al.[161]	cCLD	197	Median 43 months	>825 ms, higher risk of decompensation
	Pavlides et al.[160]	cCLD	121	Median 27 months	LIF2 (equivalent to 825 ms), higher risk of decompensation

Abbreviations: cCLD, compensated chronic liver disease; cT1, iron corrected T1; HCC, hepatocellular cancer; LIF, liver inflammation and fibrosis score; LSM, liver stiffness measurement; MR, magnetic resonance; NAFLD, nonalcoholic fatty liver disease; PBC, primary biliary cholangitis; PSC, primary sclerosing cholangitis.

693 patient-years). The latest study found that a cut-off of liver cT1 of 825 ms was predictive of clinical outcomes with an HR of 9.9 (95% CI: 1.29–76.4, $p = 0.007$),[161] while in the study by Pavlides et al.,[160] the combination of iron corrected T1 (as a surrogate of fibrosis/inflammation), T2* (as a surrogate of liver iron deposition), and PDFF (as a surrogate of liver fat accumulation) let to improved performance, illustrating the value of MRI in assessing multiple aspects of disease in one scanning session. While these are still early data, it should be noted that the cut-off of 825 ms was first identified from the associations of liver cT1 with histologically assessed liver fibrosis,[77] was then tested as a predefined cut-off in the two studies of prognosis,[160,161] making this one of the few techniques where preselected cut-offs have been investigated. Table 4 provides a summary of studies that examined MR technologies for the prediction of clinical outcomes.

9 | DISCUSSION

In this manuscript, we provide a narrative review of how MR technologies can be used to assess multiple aspects of care in patients with liver cirrhosis. While our paper aims to highlight the advances and potential of MR technology it should also be noted that MR techniques also have disadvantages that need to be taken into consideration. MR is not widely available in comparison to an alternative imaging method and is also more expensive. Some of the techniques like MRE need additional hardware, while some promising protocols like azygos vein flow and SMA velocity measurements have not been replicated outside specialist MR centers. Furthermore, the available data are still preliminary and in many cases without validation of pre-specified cut-offs for diagnosis or prognosis. Lastly, there is a lack of cost-effectiveness data to guide healthcare providers.

10 | FUTURE DIRECTIONS

MR techniques for the assessment of liver cirrhosis remain an exciting area of research with the potential to transform the care of patients. To capitalize on existing data, future studies should focus on addressing existing data gaps in the literature like the validation of pre-specified cut-offs and the assessment of techniques in intention to diagnose analyses in appropriately conducted prospective studies. Furthermore, technical developments to shorten scanning times and combine protocols into single scanning sessions can also improve patient care. Although not discussed in this manuscript, artificial intelligence and its application in MRI images[162] can also magnify the potential of these techniques and decrease the workload of radiologists, something that can help with wider adoption.

11 | CONCLUSIONS

Patients with liver disease are currently assessed with liver biopsy for the diagnosis of cirrhosis, with measurement of the hepatic vein pressure gradient and endoscopy for the assessment of portal hypertension severity with ultrasound for the screening of HCC and with blood tests and clinical assessment for the evaluation of overall disease severity and risk stratification of clinical outcomes. For the relevant information from the above tests to be collected, patients have to

27705846, 2022, 1, Downloaded from https://onlinelibrary.wiley.com/doi/10.1002/poh2.6 by Cochrane Canada Provision, Wiley Online Library on [12/12/2023]. See the Terms and Conditions (https://onlinelibrary.wiley.com/terms-and-conditions) on Wiley Online Library for rules of use; OA articles are governed by the applicable Creative Commons License

attend multiple appointments for clinic reviews and invasive tests. As we have shown in this review, MRI technologies have the potential to offer real alternatives for the assessment of patients that can be simplified into one single scanning session that is quick and completely noninvasive.

AUTHOR CONTRIBUTIONS

Osama Alzoubi and Michael Pavlides did the literature review. Osama Alzoubi, Ahmad Arar, Viraj Singh, and Michael Pavlides wrote the first draft of the manuscript. Sukru M. Erturk provided critical revisions and suggested further key references for inclusion in the review. Ferenc Mozes contributed to the preparation of the figures. All authors critically revised the manuscript for intellectual content and approved the submitted version.

ACKNOWLEDGMENT

Michael Pavlides acknowledges support from the Oxford NIHR Biomedical Research center.

CONFLICT OF INTEREST

Michael Pavlides is a shareholder in Perspectum Ltd. Michael Pavlides is the Editorial Board Member of *Portal Hypertension & Cirrhosis*, who is therefore excluded from the peer-review process and all editorial decisions related to the publication of this manuscript. The remaining authors declare no conflict of interest.

DATA AVAILABILITY STATEMENT

All the data are included in the manuscript, figures, and tables.

ETHICS STATEMENT

Not applicable. This is a narrative review of the literature.

ORCID

Osama Alzoubi http://orcid.org/0000-0001-8196-3922
Ahmad Arar http://orcid.org/0000-0002-9172-8958
Michael Pavlides http://orcid.org/0000-0001-9882-8874

REFERENCES

1. Pavlides M, Cobbold J. Non-alcoholic fatty liver disease. *Medicine*. 2019;47:728-733. doi:10.1016/j.mpmed.2019.08.007
2. Ginès P, Krag A, Abraldes JG, Solà E, Fabrellas N, Kamath PS. Liver cirrhosis. *Lancet*. 2021;398:1359-1376. doi:10.1016/S0140-6736(21)01374-X
3. Pellicoro A, Ramachandran P, Iredale JP, Fallowfield JA. Liver fibrosis and repair: immune regulation of wound healing in a solid organ. *Nat Rev Immunol*. 2014;14:181-194. doi:10.1038/nri3623
4. Bloch F, Hansen WW, Packard M. The nuclear induction experiment. *Phys Rev*. 1946;70:474-485. doi:10.1103/PhysRev.70.460
5. Purcell EM, Torrey HC, Pound RV. Resonance absorption by nuclear magnetic moments in a solid. *Phys Rev*. 1946;69:37-38. doi:10.1103/PhysRev.69.37
6. Mansfield P, Maudsley AA. Medical imaging by NMR. *Br J Radiol*. 1977;50:188-194. doi:10.1259/0007-1285-50-591-188
7. Mansfield P, Pykett IL, Morris PG. Human whole body line-scan imaging by NMR. *Br J Radiol*. 1978;51:921-922. doi:10.1259/0007-1285-51-611-921
8. Smith FW, Mallard JR, Reid A, Hutchison JM. Nuclear magnetic resonance tomographic imaging in liver disease. *Lancet*. 1981;1:963-966. doi:10.1016/S0140-6736(81)91731-1
9. Doyle FH, Pennock JM, Banks LM, et al. Nuclear magnetic resonance imaging of the liver: initial experience. *AJR Am J Roentgenol*. 1982;138:193-200. doi:10.2214/ajr.138.2.193
10. Wilman HR, Kelly M, Garratt S, et al. Characterisation of liver fat in the UK Biobank cohort. *PLoS One*. 2017;12:e0172921. doi:10.1371/journal.pone.0176867
11. Tunnicliffe EM, Banerjee R, Pavlides M, Neubauer S, Robson MD. A model for hepatic fibrosis: the competing effects of cell loss and iron on shortened modified Look-Locker inversion recovery T(1) (shMOLLI-T(1)) in the liver. *J Magn Reson Imaging*. 2017;45:450-462. doi:10.1002/jmri.25392
12. Rouvière O, Yin M, Dresner MA, et al. MR elastography of the liver: preliminary results. *Radiology*. 2006;240:440-448. doi:10.1148/radiol.2402050606
13. Matsui O, Kobayashi S, Sanada J, et al. Hepatocelluar nodules in liver cirrhosis: hemodynamic evaluation (angiography-assisted CT) with special reference to multi-step hepatocarcinogenesis. *Abdom Imaging*. 2011;36:264-272. doi:10.1007/s00261-011-9685-1
14. Forner A, Vilana R, Ayuso C, et al. Diagnosis of hepatic nodules 20 mm or smaller in cirrhosis: prospective validation of the noninvasive diagnostic criteria for hepatocellular carcinoma. *Hepatology*. 2008;47:97-104. doi:10.1002/hep.21966
15. Sangiovanni A, Manini MA, Iavarone M, et al. The diagnostic and economic impact of contrast imaging techniques in the diagnosis of small hepatocellular carcinoma in cirrhosis. *Gut*. 2010;59:638-644. doi:10.1136/gut.2009.187286
16. Chernyak V, Fowler KJ, Kamaya A, et al. Liver Imaging Reporting and Data System (LI-RADS) version 2018: imaging of hepatocellular carcinoma in at-risk patients. *Radiology*. 2018;289:816-830. doi:10.1148/radiol.2018181494
17. Guo J, Seo Y, Ren S, et al. Diagnostic performance of contrast-enhanced multidetector computed tomography and gadoxetic acid disodium-enhanced magnetic resonance imaging in detecting hepatocellular carcinoma: direct comparison and a meta-analysis. *Abdom Radiol*. 2016;41:1960-1972. doi:10.1007/s00261-016-0807-7
18. Di Martino M, De Filippis G, De Santis A, et al. Hepatocellular carcinoma in cirrhotic patients: prospective comparison of US, CT and MR imaging. *Eur Radiol*. 2013;23:887-896. doi:10.1007/s00330-012-2691-z
19. Ye F, Liu J, Ouyang H. Gadolinium ethoxybenzyl diethylenetriamine pentaacetic acid (Gd-EOB-DTPA)-enhanced magnetic resonance imaging and multidetector-row computed tomography for the diagnosis of hepatocellular carcinoma: a systematic review and meta-analysis. *Medicine (Baltimore)*. 2015;94:e1157. doi:10.1097/MD.0000000000001157
20. Omata M, Cheng AL, Kokudo N, et al. Asia-Pacific clinical practice guidelines on the management of hepatocellular carcinoma: a 2017 update. *Hepatol Int*. 2017;11:317-370. doi:10.1007/s12072-017-9799-9
21. Pan J, Tao Y, Chi X, Yang L, Zhao Y, Chen F. Do transition and hepatobiliary phase hypointensity improve LI-RADS categorization as an alternative washout: a systematic review and meta-analysis. *Eur Radiol*. 2022. doi:10.1007/s00330-022-08665-y
22. Park HJ, Jang HY, Kim SY, et al. Non-enhanced magnetic resonance imaging as a surveillance tool for hepatocellular carcinoma: comparison with ultrasound. *J Hepatol*. 2020;72:718-724. doi:10.1016/j.jhep.2019.12.001
23. Tzartzeva K, Obi J, Rich NE, et al. Surveillance imaging and alpha fetoprotein for early detection of hepatocellular carcinoma in patients with cirrhosis: a meta-analysis. *Gastroenterology*. 2018;154:1706.e-1718.e. doi:10.1053/j.gastro.2018.01.064
24. Gupta P, Soundararajan R, Patel A, Kumar-M P, Sharma V, Kalra N. Abbreviated MRI for hepatocellular carcinoma screening: a systematic review and meta-analysis. *J Hepatol*. 2021;75:108-119. doi:10.1016/j.jhep.2021.01.041
25. Chan MV, Huo YR, Trieu N, et al. Noncontrast MRI for hepatocellular carcinoma detection: a systematic review and

27705846, 2022, 1, Downloaded from https://onlinelibrary.wiley.com/doi/10.1002/poh2.6 by Cochrane Canada Provision, Wiley Online Library on [12/12/2023]. See the Terms and Conditions (https://onlinelibrary.wiley.com/terms-and-conditions) on Wiley Online Library for rules of use; OA articles are governed by the applicable Creative Commons License

meta-analysis—a potential surveillance tool. *Clin Gastroenterol Hepatol*. 2022;20:44.e-56.e. doi:10.1016/j.cgh.2021.02.036
26. Kim SY, An J, Lim YS, et al. MRI with liver-specific contrast for surveillance of patients with cirrhosis at high risk of hepatocellular carcinoma. *JAMA Oncol*. 2017;3:456-463. doi:10.1001/jamaoncol.2016.3147
27. European Medicines Agency. *EMA's final opinion confirms restrictions on use of linear gadolinium agents in body scan*. 2017. Accessed 28th April 2022. https://www.ema.europa.eu/en/documents/referral/gadolinium-article-31-referral-emas-final-opinion-confirms-restrictions-use-linear-gadolinium-agents_en.pdf
28. An C, Kim DY, Choi JY, Han KH, Roh YH, Kim MJ. Noncontrast magnetic resonance imaging versus ultrasonography for hepatocellular carcinoma surveillance (MIRACLE-HCC): study protocol for a prospective randomized trial. *BMC Cancer*. 2018;18:915. doi:10.1186/s12885-018-4827-2
29. Sutherland T, Watts J, Ryan M, et al. Diffusion-weighted MRI for hepatocellular carcinoma screening in chronic liver disease: direct comparison with ultrasound screening. *J Med Imaging Radiat Oncol*. 2017;61:34-39. doi:10.1111/1754-9485.12513
30. Kutaiba N, Ardalan Z. Risk factors and screening intervals are crucial for evaluating the cost effectiveness of abbreviated MRI in HCC screening. *J Hepatol*. 2021;75:1258-1259. doi:10.1016/j.jhep.2021.06.041
31. Pavlides M, Francis S, Barnes E. Abbreviated MRI to screen for HCC in patients with cirrhosis. A step forward but a long road ahead. *J Hepatol*. 2022;76:981-982. doi:10.1016/j.jhep.2021.10.027
32. Menon U, Gentry-Maharaj A, Burnell M, et al. Ovarian cancer population screening and mortality after long-term follow-up in the UK Collaborative Trial of Ovarian Cancer Screening (UKCTOCS): a randomised controlled trial. *Lancet*. 2021;397:2182-2193. doi:10.1016/S0140-6736(21)00731-5
33. Tsochatzis EA, Bosch J, Burroughs AK. Liver cirrhosis. *Lancet*. 2014;383:1749-1761. doi:10.1016/S0140-6736(14)60121-5
34. Williams CD, Stengel J, Asike MI, et al. Prevalence of nonalcoholic fatty liver disease and nonalcoholic steatohepatitis among a largely middle-aged population utilizing ultrasound and liver biopsy: a prospective study. *Gastroenterology*. 2011;140:124-131. doi:10.1053/j.gastro.2010.09.038
35. Jayaswal ANA, Levick C, Collier J, et al. Liver cT1 decreases following direct-acting antiviral therapy in patients with chronic hepatitis C virus. *Abdom Radiol*. 2021;46:1947-1957. doi:10.1007/s00261-020-02860-5
36. Ellis EL, Mann DA. Clinical evidence for the regression of liver fibrosis. *J Hepatol*. 2012;56:1171-1180. doi:10.1016/j.jhep.2011.09.024
37. Rockey DC, Caldwell SH, Goodman ZD, Nelson RC, Smith AD. Liver biopsy. *Hepatology*. 2009;49:1017-1044. doi:10.1002/hep.22742
38. Carey E, Carey WD. Noninvasive tests for liver disease, fibrosis, and cirrhosis: is liver biopsy obsolete? *Cleve Clin J Med*. 2010;77:519-527. doi:10.3949/ccjm.77a.09138
39. Regev A, Berho M, Jeffers LJ, et al. Sampling error and intraobserver variation in liver biopsy in patients with chronic HCV infection. *Am J Gastroenterol*. 2002;97:2614-2618. doi:10.1111/j.1572-0241.2002.06038.x
40. Bedossa P, Dargère D, Paradis V. Sampling variability of liver fibrosis in chronic hepatitis C. *Hepatology*. 2003;38:1449-1457. doi:10.1053/jhep.2003.09022
41. Dulai PS, Sirlin CB, Loomba R. MRI and MRE for non-invasive quantitative assessment of hepatic steatosis and fibrosis in NAFLD and NASH: clinical trials to clinical practice. *J Hepatol*. 2016;65:1006-1016. doi:10.1016/j.jhep.2016.06.005
42. Sumida Y, Nakajima A, Itoh Y. Limitations of liver biopsy and non-invasive diagnostic tests for the diagnosis of nonalcoholic fatty liver disease/nonalcoholic steatohepatitis. *World J Gastroenterol*. 2014;20:475-485. doi:10.3748/wjg.v20.i2.475
43. Hagan M, Asrani SK, Talwalkar J. Non-invasive assessment of liver fibrosis and prognosis. *Expert Rev Gastroenterol Hepatol*. 2015;9:1251-1260. doi:10.1586/17474124.2015.1075391
44. Mózes FE, Lee JA, Selvaraj EA, et al. Diagnostic accuracy of non-invasive tests for advanced fibrosis in patients with NAFLD: an individual patient data meta-analysis. *Gut*. 2022;71:1006-1019. doi:10.1136/gutjnl-2021-324243
45. Vali Y, Lee J, Boursier J, et al. Enhanced liver fibrosis test for the non-invasive diagnosis of fibrosis in patients with NAFLD: a systematic review and meta-analysis. *J Hepatol*. 2020;73:252-262. doi:10.1016/j.jhep.2020.03.036
46. Venkatesh SK, Ehman RL. Magnetic resonance elastography of liver. *Magn Reson Imaging Clin N Am*. 2014;22:433-446. doi:10.1016/j.mric.2014.05.001
47. Schuppan D, Afdhal NH. Liver cirrhosis. *Lancet*. 2008;371:838-851. doi:10.1016/S0140-6736(08)60383-9
48. Petitclerc L, Gilbert G, Nguyen BN, Tang A. Liver fibrosis quantification by magnetic resonance imaging. *Top Magn Reson Imaging*. 2017;26:229-241. doi:10.1097/RMR.0000000000000149
49. Petitclerc L, Sebastiani G, Gilbert G, Cloutier G, Tang A. Liver fibrosis: review of current imaging and MRI quantification techniques. *J Magn Reson Imaging*. 2017;45:1276-1295. doi:10.1002/jmri.25550
50. Lefebvre T, Wartelle-Bladou C, Wong P, et al. Prospective comparison of transient, point shear wave, and magnetic resonance elastography for staging liver fibrosis. *Eur Radiol*. 2019;29:6477-6488. doi:10.1007/s00330-019-06331-4
51. Cui J, Ang B, Haufe W, et al. Comparative diagnostic accuracy of magnetic resonance elastography vs. eight clinical prediction rules for non-invasive diagnosis of advanced fibrosis in biopsy-proven non-alcoholic fatty liver disease: a prospective study. *Aliment Pharmacol Ther*. 2015;41:1271-1280. doi:10.1111/apt.13196
52. Xiao G, Zhu S, Xiao X, Yan L, Yang J, Wu G. Comparison of laboratory tests, ultrasound, or magnetic resonance elastography to detect fibrosis in patients with nonalcoholic fatty liver disease: a meta-analysis. *Hepatology*. 2017;66:1486-1501. doi:10.1002/hep.29302
53. Morisaka H, Motosugi U, Ichikawa S, et al. Magnetic resonance elastography is as accurate as liver biopsy for liver fibrosis staging. *J Magn Reson Imaging*. 2018;47:1268-1275. doi:10.1002/jmri.25868
54. Toguchi M, Tsurusaki M, Yada N, et al. Magnetic resonance elastography in the assessment of hepatic fibrosis: a study comparing transient elastography and histological data in the same patients. *Abdom Radiol (NY)*. 2017;42:1659-1666. doi:10.1007/s00261-017-1045-3
55. Guo Y, Parthasarathy S, Goyal P, McCarthy RJ, Larson AC, Miller FH. Magnetic resonance elastography and acoustic radiation force impulse for staging hepatic fibrosis: a meta-analysis. *Abdom Imaging*. 2015;40:818-834. doi:10.1007/s00261-014-0137-6
56. Imajo K, Kessoku T, Honda Y, et al. Magnetic resonance imaging more accurately classifies steatosis and fibrosis in patients with nonalcoholic fatty liver disease than transient elastography. *Gastroenterology*. 2016;150:626.e-637.e. doi:10.1053/j.gastro.2015.11.048
57. Bohte AE, de Niet A, Jansen L, et al. Non-invasive evaluation of liver fibrosis: a comparison of ultrasound-based transient elastography and MR elastography in patients with viral hepatitis B and C. *Eur Radiol*. 2014;24:638-648. doi:10.1007/s00330-013-3046-0
58. Huwart L, Sempoux C, Vicaut E, et al. Magnetic resonance elastography for the noninvasive staging of liver fibrosis. *Gastroenterology*. 2008;135:32-40. doi:10.1053/j.gastro.2008.03.076
59. Dyvorne HA, Jajamovich GH, Bane O, et al. Prospective comparison of magnetic resonance imaging to transient elastography and serum markers for liver fibrosis detection. *Liver Int*. 2016;36:659-666. doi:10.1111/liv.13058
60. Chen J, Yin M, Talwalkar JA, et al. Diagnostic performance of MR elastography and vibration-controlled transient elastography in the detection of hepatic fibrosis in patients with severe to morbid obesity. *Radiology*. 2017;283:418-428. doi:10.1148/radiol.2016160685
61. Van Beers BE, Daire JL, Garteiser P. New imaging techniques for liver diseases. *J Hepatol*. 2015;62:690-700. doi:10.1016/j.jhep.2014.10.014
62. Castéra L, Foucher J, Bernard PH, et al. Pitfalls of liver stiffness measurement: a 5-year prospective study of 13,369 examinations. *Hepatology*. 2010;51:828-835. doi:10.1002/hep.23425

27705846, 2022, 1, Downloaded from https://onlinelibrary.wiley.com/doi/10.1002/poh2.6 by Cochrane Canada Provision, Wiley Online Library on [12/12/2023]. See the Terms and Conditions (https://onlinelibrary.wiley.com/terms-and-conditions) on Wiley Online Library for rules of use; OA articles are governed by the applicable Creative Commons License

63. Mathew RP, Venkatesh SK. Imaging of hepatic fibrosis. *Curr Gastroenterol Rep*. 2018;20:45. doi:10.1007/s11894-018-0652-7
64. Rustogi R, Horowitz J, Harmath C, et al. Accuracy of MR elastography and anatomic MR imaging features in the diagnosis of severe hepatic fibrosis and cirrhosis. *J Magn Reson Imaging*. 2012;35:1356-1364. doi:10.1002/jmri.23585
65. Venkatesh SK, Yin M, Takahashi N, Glockner JF, Talwalkar JA, Ehman RL. Non-invasive detection of liver fibrosis: MR imaging features vs. MR elastography. *Abdom Imaging*. 2015;40:766-775. doi:10.1007/s00261-015-0347-6
66. Liang Y, Li D. Magnetic resonance elastography in staging liver fibrosis in non-alcoholic fatty liver disease: a pooled analysis of the diagnostic accuracy. *BMC Gastroenterol*. 2020;20:89. doi:10.1186/s12876-020-01234-x
67. Selvaraj EA, Mózes FE, Jayaswal ANA, et al. Diagnostic accuracy of elastography and magnetic resonance imaging in patients with NAFLD: a systematic review and meta-analysis. *J Hepatol*. 2021;75:770-785. doi:10.1016/j.jhep.2021.04.044
68. Singh S, Venkatesh SK, Loomba R, et al. Magnetic resonance elastography for staging liver fibrosis in non-alcoholic fatty liver disease: a diagnostic accuracy systematic review and individual participant data pooled analysis. *Eur Radiol*. 2016;26:1431-1440. doi:10.1007/s00330-015-3949-z
69. Wang Y, Ganger DR, Levitsky J, et al. Assessment of chronic hepatitis and fibrosis: comparison of MR elastography and diffusion-weighted imaging. *AJR Am J Roentgenol*. 2011;196:553-561. doi:10.2214/AJR.10.4580
70. Loomba R, Wolfson T, Ang B, et al. Magnetic resonance elastography predicts advanced fibrosis in patients with nonalcoholic fatty liver disease: a prospective study. *Hepatology*. 2014;60:1920-1928. doi:10.1002/hep.27362
71. Yoneda M, Suzuki K, Kato S, et al. Nonalcoholic fatty liver disease: US-based acoustic radiation force impulse elastography. *Radiology*. 2010;256:640-647. doi:10.1148/radiol.10091662
72. Yin M, Talwalkar JA, Glaser KJ, et al. Assessment of hepatic fibrosis with magnetic resonance elastography. *Clin Gastroenterol Hepatol*. 2007;5:1207.e-1213.e. doi:10.1016/j.cgh.2007.06.012
73. Venkatesh SK, Wang G, Teo LL, Ang BW. Magnetic resonance elastography of liver in healthy Asians: normal liver stiffness quantification and reproducibility assessment. *J Magn Reson Imaging*. 2014;39:1-8. doi:10.1002/jmri.24084
74. Zhang E, Wartelle-Bladou C, Lepanto L, Lachaine J, Cloutier G, Tang A. Cost-utility analysis of nonalcoholic steatohepatitis screening. *Eur Radiol*. 2015;25:3282-3294. doi:10.1007/s00330-015-3731-2
75. Navin PJ, Hilscher MB, Welle CL, et al. The utility of MR elastography to differentiate nodular regenerative hyperplasia from cirrhosis. *Hepatology*. 2019;69:452-454. doi:10.1002/hep.30175
76. Pavlides M, Banerjee R, Tunnicliffe EM, et al. Multiparametric magnetic resonance imaging for the assessment of non-alcoholic fatty liver disease severity. *Liver Int*. 2017;37:1065-1073. doi:10.1111/liv.13284
77. Banerjee R, Pavlides M, Tunnicliffe EM, et al. Multiparametric magnetic resonance for the non-invasive diagnosis of liver disease. *J Hepatol*. 2014;60:69-77. doi:10.1016/j.jhep.2013.09.002
78. Harrison SA, Dennis A, Fiore MM, et al. Utility and variability of three non-invasive liver fibrosis imaging modalities to evaluate efficacy of GR-MD-02 in subjects with NASH and bridging fibrosis during a phase-2 randomized clinical trial. *PLoS One*. 2018;13:e0203054. doi:10.1371/journal.pone.0203054
79. McDonald N, Eddowes PJ, Hodson J, et al. Multiparametric magnetic resonance imaging for quantitation of liver disease: a two-centre cross-sectional observational study. *Sci Rep*. 2018;8:9189. doi:10.1038/s41598-018-27560-5
80. Eddowes PJ, McDonald N, Davies N, et al. Utility and cost evaluation of multiparametric magnetic resonance imaging for the assessment of non-alcoholic fatty liver disease. *Aliment Pharmacol Ther*. 2018;47:631-644. doi:10.1111/apt.14469
81. Dennis A, Kelly MD, Fernandes C, et al. Correlations between MRI biomarkers PDFF and cT1 with histopathological features of non-alcoholic steatohepatitis. *Front Endocrinol (Lausanne)*. 2020;11:575843. doi:10.3389/fendo.2020.575843
82. Harrison SA, Gawrieh S, Roberts K, et al. Prospective evaluation of the prevalence of non-alcoholic fatty liver disease and steatohepatitis in a large middle-aged US cohort. *J Hepatol*. 2021;75:284-291. doi:10.1016/j.jhep.2021.02.034
83. Imajo K, Tetlow L, Dennis A, et al. Quantitative multiparametric magnetic resonance imaging can aid non-alcoholic steatohepatitis diagnosis in a Japanese cohort. *World J Gastroenterol*. 2021;27:609-623. doi:10.3748/wjg.v27.i7.609
84. Andersson A, Kelly M, Imajo K, et al. Clinical utility of magnetic resonance imaging biomarkers for identifying nonalcoholic steatohepatitis patients at high risk of progression: a multicenter pooled data and meta-analysis. *Clin Gastroenterol Hepatol*. 2021. doi:10.1016/j.cgh.2021.09.041
85. Ryan JD, Armitage AE, Cobbold JF, et al. Hepatic iron is the major determinant of serum ferritin in NAFLD patients. *Liver Int*. 2018;38:164-173. doi:10.1111/liv.13513
86. Arndtz K, Shumbayawonda E, Hodson J, et al. Multiparametric magnetic resonance imaging, autoimmune hepatitis, and prediction of disease activity. *Hepatol Commun*. 2021;5:1009-1020. doi:10.1002/hep4.1687
87. Janowski K, Shumbayawonda E, Cheng L, et al. Quantitative multiparametric MRI as a non-invasive stratification tool in children and adolescents with autoimmune liver disease. *Sci Rep*. 2021;11:15261. doi:10.1038/s41598-021-94754-9
88. Amerikanou C, Kanoni S, Kaliora AC, et al. Effect of Mastiha supplementation on NAFLD: the MAST4HEALTH randomised, controlled trial. *Mol Nutr Food Res*. 2021;65:e2001178. doi:10.1002/mnfr.202001178
89. McKay A, Wilman HR, Dennis A, et al. Measurement of liver iron by magnetic resonance imaging in the UK Biobank population. *PLoS One*. 2018;13:e0209340. doi:10.1371/journal.pone.0209340
90. Gallego-Durán R, Cerro-Salido P, Gomez-Gonzalez E, et al. Imaging biomarkers for steatohepatitis and fibrosis detection in non-alcoholic fatty liver disease. *Sci Rep*. 2016;6:31421. doi:10.1038/srep31421
91. Bonekamp S, Torbenson MS, Kamel IR. Diffusion-weighted magnetic resonance imaging for the staging of liver fibrosis. *J Clin Gastroenterol*. 2011;45:885-892. doi:10.1097/MCG.0b013e318223bd2c
92. Lee KS, Muñoz A, Báez AB, Ngo L, Rofsky NM, Pedrosa I. Corticomedullary differentiation on T1-weighted MRI: comparison between cirrhotic and noncirrhotic patients. *J Magn Reson Imaging*. 2012;35:644-649. doi:10.1002/jmri.22852
93. Hoffman DH, Ayoola A, Nickel D, Han F, Chandarana H, Shanbhogue KP. T1 mapping, T2 mapping and MR elastography of the liver for detection and staging of liver fibrosis. *Abdom Radiol (NY)*. 2020;45:692-700. doi:10.1007/s00261-019-02382-9
94. D'Amico G, Morabito A, D'Amico M, et al. Clinical states of cirrhosis and competing risks. *J Hepatol*. 2018;68:563-576. doi:10.1016/j.jhep.2017.10.020
95. Garcia-Tsao G, Abraldes JG, Berzigotti A, Bosch J. Portal hypertensive bleeding in cirrhosis: risk stratification, diagnosis, and management: 2016 practice guidance by the American Association for the study of liver diseases. *Hepatology*. 2017;65:310-335. doi:10.1002/hep.28906
96. Bosch J, Abraldes JG, Berzigotti A, García-Pagan JC. The clinical use of HVPG measurements in chronic liver disease. *Nat Rev Gastroenterol Hepatol*. 2009;6:573-582. doi:10.1038/nrgastro.2009.149
97. de Franchis R. Expanding consensus in portal hypertension: report of the Baveno VI consensus workshop: stratifying risk and individualizing care for portal hypertension. *J Hepatol*. 2015;63:743-752. doi:10.1016/j.jhep.2015.05.022
98. Merkel C, Bolognesi M, Sacerdoti D, et al. The hemodynamic response to medical treatment of portal hypertension as a predictor of clinical effectiveness in the primary prophylaxis of variceal bleeding in cirrhosis. *Hepatology*. 2000;32:930-934. doi:10.1053/jhep.2000.19322
99. Villanueva C, Albillos A, Genescà J, et al. blockers to prevent decompensation of cirrhosis in patients with clinically significant portal hypertension (PREDESCI): a randomised, double-blind, placebo-controlled, multicentre trial. *Lancet*. 2019;393:1597-1608. doi:10.1016/S0140-6736(18)31875-0

27705846, 2022, 1, Downloaded from https://onlinelibrary.wiley.com/doi/10.1002/poh2.6 by Cochrane Canada Provision, Wiley Online Library on [12/12/2023]. See the Terms and Conditions (https://onlinelibrary.wiley.com/terms-and-conditions) on Wiley Online Library for rules of use; OA articles are governed by the applicable Creative Commons License

100. Qi X, Berzigotti A, Cardenas A, Sarin SK. Emerging non-invasive approaches for diagnosis and monitoring of portal hypertension. *Lancet Gastroenterol Hepatol*. 2018;3:708-719. doi:10.1016/S2468-1253(18)30232-2
101. Elkrief L, Rautou PE, Ronot M, et al. Prospective comparison of spleen and liver stiffness by using shear-wave and transient elastography for detection of portal hypertension in cirrhosis. *Radiology*. 2015;275:589-598. doi:10.1148/radiol.14141210
102. Vizzutti F, Arena U, Romanelli RG, et al. Liver stiffness measurement predicts severe portal hypertension in patients with HCV-related cirrhosis. *Hepatology*. 2007;45:1290-1297. doi:10.1002/hep.21665
103. You MW, Kim KW, Pyo J, et al. A Meta-analysis for the diagnostic performance of transient elastography for clinically significant portal hypertension. *Ultrasound Med Biol*. 2017;43:59-68. doi:10.1016/j.ultrasmedbio.2016.07.025
104. Singh S, Venkatesh SK, Keaveny A, et al. Diagnostic accuracy of magnetic resonance elastography in liver transplant recipients: a pooled analysis. *Ann Hepatol*. 2016;15:363-376. doi:10.5604/16652681.1198808
105. Wagner M, Hectors S, Bane O, et al. Noninvasive prediction of portal pressure with MR elastography and DCE-MRI of the liver and spleen: preliminary results. *J Magn Reson Imaging*. 2018;48:1091-1103. doi:10.1002/jmri.26026
106. Gharib AM, Han MAT, Meissner EG, et al. Magnetic resonance elastography shear wave velocity correlates with liver fibrosis and hepatic venous pressure gradient in adults with advanced liver disease. *BioMed Res Int*. 2017;2017:2067479. doi:10.1155/2017/2067479
107. Ronot M, Lambert S, Elkrief L, et al. Assessment of portal hypertension and high-risk oesophageal varices with liver and spleen three-dimensional multifrequency MR elastography in liver cirrhosis. *Eur Radiol*. 2014;24:1394-1402. doi:10.1007/s00330-014-3124-y
108. Yin M, Kolipaka A, Woodrum DA, et al. Hepatic and splenic stiffness augmentation assessed with MR elastography in an in vivo porcine portal hypertension model. *J Magn Reson Imaging*. 2013;38:809-815. doi:10.1002/jmri.24049
109. Shin SU, Lee JM, Yu MH, et al. Prediction of esophageal varices in patients with cirrhosis: usefulness of three-dimensional MR elastography with echo-planar imaging technique. *Radiology*. 2014;272:143-153. doi:10.1148/radiol.14130916
110. Matsui N, Imajo K, Yoneda M, et al. Magnetic resonance elastography increases usefulness and safety of non-invasive screening for esophageal varices. *J Gastroenterol Hepatol*. 2018;33:2022-2028. doi:10.1111/jgh.14298
111. Hoffman DH, Ayoola A, Nickel D, et al. MR elastography, T1 and T2 relaxometry of liver: role in noninvasive assessment of liver function and portal hypertension. *Abdom Radiol (NY)*. 2020;45:2680-2687. doi:10.1007/s00261-020-02432-7
112. Sun HY, Lee JM, Han JK, Choi BI. Usefulness of MR elastography for predicting esophageal varices in cirrhotic patients. *J Magn Reson Imaging*. 2014;39:559-566. doi:10.1002/jmri.24186
113. Hoad CL, Palaniyappan N, Kaye P, et al. A study of T1 relaxation time as a measure of liver fibrosis and the influence of confounding histological factors. *NMR Biomed*. 2015;28:706-714. doi:10.1002/nbm.3299
114. Luetkens JA, Klein S, Träber F, et al. Quantification of liver fibrosis at T1 and T2 mapping with extracellular volume fraction MRI: preclinical results. *Radiology*. 2018;288:748-754. doi:10.1148/radiol.2018180051
115. Levick C, Phillips-Hughes J, Collier J, et al Non-invasive assessment of portal hypertension by multi-parametric magnetic resonance imaging of the spleen: a proof of concept study. *PLoS One*. 2019;14:e0221066. doi:10.1371/journal.pone.022106
116. Hectors SJ, Bane O, Stocker D, et al. Splenic T1ρ as a noninvasive biomarker for portal hypertension. *J Magn Reson Imaging*. 2020;52:787-794. doi:10.1002/jmri.27087
117. Hectors SJ, Bane O, Kennedy P, et al. T(1ρ) mapping for assessment of renal allograft fibrosis. *J Magn Reson Imaging*. 2019;50:1085-1091. doi:10.1002/jmri.26656
118. Menezes NM, Gray ML, Hartke JR, Burstein D. T2 and T1rho MRI in articular cartilage systems. *Magn Reson Med*. 2004;51:503-509. doi:10.1002/mrm.10710
119. Wáng YXJ, Chen W, Deng M. How liver pathologies contribute to T1rho contrast require more careful studies. *Quant Imaging Med Surg*. 2017;7:608-613. doi:10.21037/qims.2017.10.02
120. Palaniyappan N, Cox E, Bradley C, et al. Non-invasive assessment of portal hypertension using quantitative magnetic resonance imaging. *J Hepatol*. 2016;65:1131-1139. doi:10.1016/j.jhep.2016.07.021
121. Mesropyan N, Isaak A, Faron A, et al. Magnetic resonance parametric mapping of the spleen for non-invasive assessment of portal hypertension. *Eur Radiol*. 2021;31:85-93. doi:10.1007/s00330-020-07080-5
122. Møller S, Henriksen JH, Bendtsen F. Extrahepatic complications to cirrhosis and portal hypertension: haemodynamic and homeostatic aspects. *World J Gastroenterol*. 2014;20:15499-15517. doi:10.3748/wjg.v20.i42.15499
123. Bosch J, García-Pagán JC. Complications of cirrhosis. I. Portal hypertension. *J Hepatol*. 2000;32(suppl 1):141-156. doi:10.1016/s0168-8278(00)80422-5
124. Denys A, Menu Y. Portal and splanchnic blood flow measurements in vivo: US Doppler or MR angiography? *J Hepatol*. 1997;26:437-438. doi:10.1016/S0168-8278(97)80064-5
125. Kok T, van der Jagt EJ, Haagsma EB, Bijleveld CM, Jansen PL, Boeve WJ. The value of Doppler ultrasound in cirrhosis and portal hypertension. *Scand J Gastroenterol Suppl*. 1999;230:82-88. doi:10.1080/003655299750025598
126. Gouya H, Grabar S, Vignaux O, et al. Portal hypertension in patients with cirrhosis: indirect assessment of hepatic venous pressure gradient by measuring azygos flow with 2D-cine phase-contrast magnetic resonance imaging. *Eur Radiol*. 2016;26:1981-1990. doi:10.1007/s00330-015-3991-x
127. Bosch J, Mastai R, Kravetz D, Bruix J, Rigau J, Rodés J. Measurement of azygos venous blood flow in the evaluation of portal hypertension in patients with cirrhosis. Clinical and haemodynamic correlations in 100 patients. *J Hepatol*. 1985;1:125-139. doi:10.1016/s0168-8278(85)80761-3
128. Mahl TC, Groszmann RJ. Pathophysiology of portal hypertension and variceal bleeding. *Surg Clin North Am*. 1990;70:251-266. doi:10.1016/s0039-6109(16)45080-2
129. Gouya H, Vignaux O, Sogni P, et al. Chronic liver disease: systemic and splanchnic venous flow mapping with optimized cine phase-contrast MR imaging validated in a phantom model and prospectively evaluated in patients. *Radiology*. 2011;261:144-155. doi:10.1148/radiol.11101541
130. Wu MT, Pan HB, Chen C, et al. Azygos blood flow in cirrhosis: measurement with MR imaging and correlation with variceal hemorrhage. *Radiology*. 1996;198:457-462. doi:10.1148/radiology.198.2.8596849
131. Burkart DJ, Johnson CD, Ehman RL, Weaver AL, Ilstrup DM. Evaluation of portal venous hypertension with cine phase-contrast MR flow measurements: high association of hyperdynamic portal flow with variceal hemorrhage. *Radiology*. 1993;188:643-648. doi:10.1148/radiology.188.3.8351326
132. Morisaka H, Motosugi U, Ichikawa T, et al. MR-based measurements of portal vein flow and liver stiffness for predicting gastroesophageal varices. *Magn Reson Med Sci*. 2013;12:77-86. doi:10.2463/mrms.2012-0052
133. Bannas P, Roldán-Alzate A, Johnson KM, et al. Longitudinal monitoring of hepatic blood flow before and after TIPS by using 4D-flow MR imaging. *Radiology*. 2016;281:574-582. doi:10.1148/radiol.2016152247
134. Roldán-Alzate A, Frydrychowicz A, Said A, et al Impaired regulation of portal venous flow in response to a meal challenge as quantified by 4D flow MRI. *J Magn Reson Imaging*. 2015;42:1009-1017. doi:10.1002/jmri.25047
135. Motosugi U, Roldán-Alzate A, Bannas P, et al. Four-dimensional flow MRI as a marker for risk stratification of gastroesophageal varices in patients with liver cirrhosis. *Radiology*. 2019;290:101-107. doi:10.1148/radiol.2018180230
136. Hectors SJ, Bane O, Kennedy P, et al. Noninvasive diagnosis of portal hypertension using gadoxetate DCE-MRI of the liver and spleen. *Eur Radiol*. 2021;31:4804-4812. doi:10.1007/s00330-020-07495-0
137. Liu Y, Tang T, Örmeci N, et al. Noncontrast-enhanced MRI-based noninvasive score for portal hypertension (CHESS1802):

27705846, 2022, 1, Downloaded from https://onlinelibrary.wiley.com/doi/10.1002/poh2.6 by Cochrane Canada Provision, Wiley Online Library on [12/12/2023]. See the Terms and Conditions (https://onlinelibrary.wiley.com/terms-and-conditions) on Wiley Online Library for rules of use; OA articles are governed by the applicable Creative Commons License

an international multicenter study. *J Clin Transl Hepatol*. 2021;9:818-827. doi:10.14218/JCTH.2021.00177
138. De Vos N, Sartoris R, Cauchy F, Rautou PE, Vilgrain V, Ronot M. Performance of liver surface nodularity quantification for the diagnosis of portal hypertension in patients with cirrhosis: comparison between MRI with hepatobiliary phase sequences and CT. *Abdom Radiol (NY)*. 2020;45:365-372. doi:10.1007/s00261-019-02355-y
139. Kumar M, Sakhuja P, Kumar A, et al. Histological subclassification of cirrhosis based on histological-haemodynamic correlation. *Aliment Pharmacol Ther*. 2008;27:771-779. doi:10.1111/j.1365-2036.2008.03653.x
140. Smith AD, Branch CR, Zand K, et al. Liver surface nodularity quantification from routine CT images as a biomarker for detection and evaluation of cirrhosis. *Radiology*. 2016;280:771-781. doi:10.1148/radiol.2016151542
141. Sartoris R, Rautou PE, Elkrief L, et al. Quantification of liver surface nodularity at CT: utility for detection of portal hypertension. *Radiology*. 2018;289:698-707. doi:10.1148/radiol.2018181131
142. Smith AD, Zand KA, Florez E, et al. Liver surface nodularity score allows prediction of cirrhosis decompensation and death. *Radiology*. 2016;283:711-722. doi:10.1148/radiol.2016160799
143. Okuda K, Ohnishi K, Kimura K, et al. Incidence of portal vein thrombosis in liver cirrhosis. An angiographic study in 708 patients. *Gastroenterology*. 1985;89:279-286. doi:10.1016/0016-5085(85)90327-0
144. Ogren M, Bergqvist D, Björck M, Acosta S, Eriksson H, Sternby NH. Portal vein thrombosis: prevalence, patient characteristics and lifetime risk: a population study based on 23,796 consecutive autopsies. *World J Gastroenterol*. 2006;12:2115-2119. doi:10.3748/wjg.v12.i13.2115
145. Cohen J, Edelman RR, Chopra S. Portal vein thrombosis: a review. *Am J Med*. 1992;92:173-182. doi:10.1016/0002-9343(92)90109-O
146. Sotiropoulos GC, Radtke A, Schmitz KJ, et al. Liver transplantation in the setting of hepatocellular carcinoma and portal vein thrombosis: a challenging dilemma? *Dig Dis Sci*. 2008;53:1994-1999. doi:10.1007/s10620-007-0099-4
147. Gawande R, Jalaeian H, Niendorf E, et al. MRI in differentiating malignant versus benign portal vein thrombosis in patients with hepatocellular carcinoma: value of post contrast imaging with subtraction. *Eur J Radiol*. 2019;118:88-95. doi:10.1016/j.ejrad.2019.07.008
148. Takizawa D, Kakizaki S, Sohara N, et al. Hepatocellular carcinoma with portal vein tumor thrombosis: clinical characteristics, prognosis, and patient survival analysis. *Dig Dis Sci*. 2007;52:3290-3295. doi:10.1007/s10620-007-9808-2
149. Catalano OA, Choy G, Zhu A, Hahn PF, Sahani DV. Differentiation of malignant thrombus from bland thrombus of the portal vein in patients with hepatocellular carcinoma: application of diffusion-weighted MR imaging. *Radiology*. 2010;254:154-162. doi:10.1148/radiol.09090304
150. Ahn JH, Yu JS, Cho ES, Chung JJ, Kim JH, Kim KW. Diffusion-weighted MRI of malignant versus benign portal vein thrombosis. *Korean J Radiol*. 2016;17:533-540. doi:10.3348/kjr.2016.17.4.533
151. Sandrasegaran K, Tahir B, Nutakki K, et al. Usefulness of conventional MRI sequences and diffusion-weighted imaging in differentiating malignant from benign portal vein thrombus in cirrhotic patients. *AJR Am J Roentgenol*. 2013;201:1211-1219. doi:10.2214/AJR.12.10171
152. D'Amico G, Garcia-Tsao G, Pagliaro L. Natural history and prognostic indicators of survival in cirrhosis: a systematic review of 118 studies. *J Hepatol*. 2006;44:217-231. doi:10.1016/j.jhep.2005.10.013
153. Asrani SK, Talwalkar JA, Kamath PS, et al. Role of magnetic resonance elastography in compensated and decompensated liver disease. *J Hepatol*. 2014;60:934-939. doi:10.1016/j.jhep.2013.12.016
154. Lee DH, Lee JM, Chang W, et al. Prognostic role of liver stiffness measurements using magnetic resonance elastography in patients with compensated chronic liver disease. *Eur Radiol*. 2018;28:3513-3521. doi:10.1007/s00330-017-5278-x
155. Gidener T, Yin M, Dierkhising RA, Allen AM, Ehman RL, Venkatesh SK. Magnetic resonance elastography for prediction of long-term progression and outcome in chronic liver disease: a retrospective study. *Hepatology*. 2022;75:379-390. doi:10.1002/hep.32151
156. Han MAT, Vipani A, Noureddin N, et al. MR elastography-based liver fibrosis correlates with liver events in nonalcoholic fatty liver patients: a multicenter study. *Liver Int*. 2020;40:2242-2251. doi:10.1111/liv.14593
157. Park JG, Jung J, Verma KK, et al. Liver stiffness by magnetic resonance elastography is associated with increased risk of cardiovascular disease in patients with non-alcoholic fatty liver disease. *Aliment Pharmacol Ther*. 2021;53:1030-1037. doi:10.1111/apt.16324
158. Osman KT, Maselli DB, Idilman IS, et al. Liver stiffness measured by either magnetic resonance or transient elastography is associated with liver fibrosis and is an independent predictor of outcomes among patients with primary biliary cholangitis. *J Clin Gastroenterol*. 2021;55:449-457. doi:10.1097/MCG.0000000000001433
159. Eaton JE, Sen A, Hoodeshenas S, et al. Changes in liver stiffness, measured by magnetic resonance elastography, associated with hepatic decompensation in patients with primary sclerosing cholangitis. *Clin Gastroenterol Hepatol*. 2020;18:1576.e-1583.e. doi:10.1016/j.cgh.2019.10.041
160. Pavlides M, Banerjee R, Sellwood J, et al. Multiparametric magnetic resonance imaging predicts clinical outcomes in patients with chronic liver disease. *J Hepatol*. 2016;64:308-315. doi:10.1016/j.jhep.2015.10.009
161. Jayaswal ANA, Levick C, Selvaraj EA, et al. Prognostic value of multiparametric magnetic resonance imaging, transient elastography and blood-based fibrosis markers in patients with chronic liver disease. *Liver Int*. 2020;40:3071-3082. doi:10.1111/liv.14625
162. Hill CE, Biasiolli L, Robson MD, Grau V, Pavlides M. Emerging artificial intelligence applications in liver magnetic resonance imaging. *World J Gastroenterol*. 2021;27:6825-6843. doi:10.3748/wjg.v27.i40.6825

How to cite this article: Alzoubi O, Arar A, Singh V, Erturk SM, Mozes F, Pavlides M. MRI in liver cirrhosis. *Port Hypertens Cirrhos*. 2022;1:23-41. doi:10.1002/poh2.6

27705846, 2022, 1, Downloaded from https://onlinelibrary.wiley.com/doi/10.1002/poh2.6 by Cochrane Canada Provision, Wiley Online Library on [12/12/2023]. See the Terms and Conditions (https://onlinelibrary.wiley.com/terms-and-conditions) on Wiley Online Library for rules of use; OA articles are governed by the applicable Creative Commons License